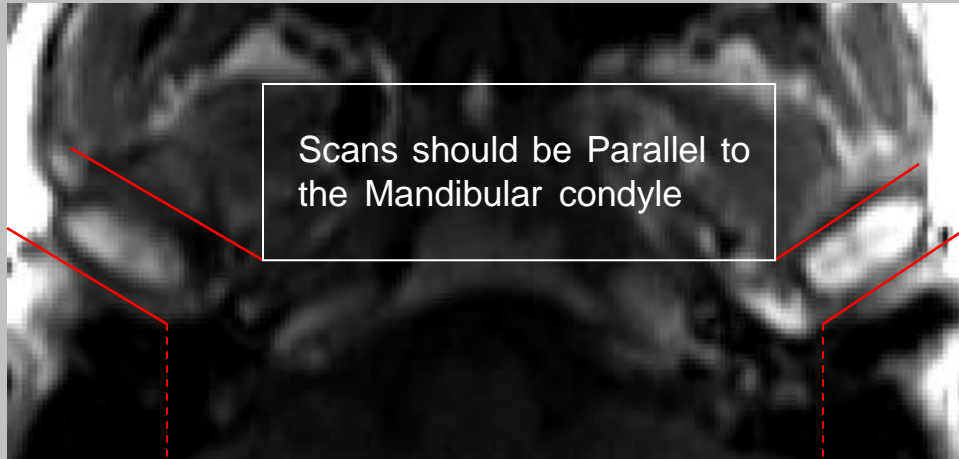


# TMJ'S

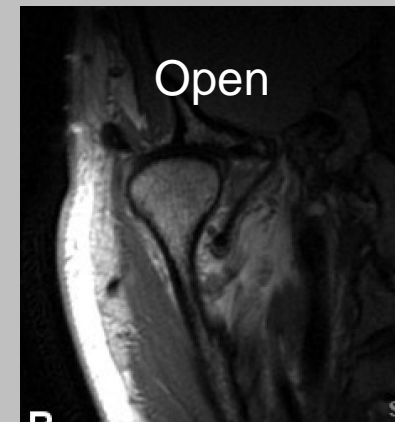
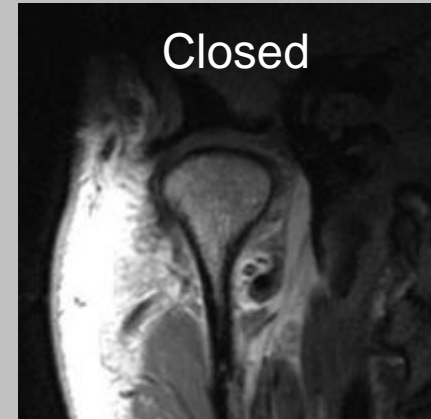
CLINICAL INDICATIONS:		H/A'S, Dislocation, Disc problems						
parameter	SERIES 1	SERIES 2	SERIES 3	SERIES 4	SERIES 5	SERIES 6	SERIES 7	SERIES 8
description	3-PLN	TI SAG	T2 SAG	GRE SAG	PD COR	PD COR	TI SAG OPEN	T2 SAG OPEN
	LOC	CLOSED	CLOSED	CLOSED	CLOSED	OPEN		
entry	supine	supine	supine	supine	supine	supine	supine	supine
position	head first	head first	head first	head first	head first	head first	head first	head first
coil plane	DUAL	DUAL	DUAL	DUAL	DUAL	DUAL	DUAL	DUAL
	3-PLN	Sagittal	Sagittal	Sagittal	CORONAL	CORONAL	Sagittal	Sagittal
pulse seq.	FGRE	Spin-Echo	FRFSE-XL	GRE	Spin-Echo	Spin-Echo	Spin-Echo	FRFSE-XL
im options		Np,EDR,TRF,Z512	Np,EDR,TRF,Z512	Np,EDR,TRF,Z512	Np,EDR,TRF,Z512	Np,EDR,TRF,Z512	Np,EDR,TRF,Z512	Np,EDR,TRF,Z512
PSD name								
Te		Min-Full	102	15	24	24	Min-Full	102
TR		500 +	3375	350	1500	1500	500 +	3375
TI								
flip angle				20				
ETL		3	23		8	8	3	23
RBW		20	20	9	18	18	20	20
SATS								
FOV	25	12	12	12	12	12	12	12
slice thick	5	2	2	2	2	2	2	2
spacing	5	0.3	0.3	0.3	0.3	0.3	0.3	0.3
F Phase	256	256	256	256	256	256	256	256
P Phase	128	192	192	192	224	224	192	192
NEX	1	4	5	3	3	3	4	5
Phase								
FOV	1	1	1	1	1	1	1	1
FREQ DIR		S/I	S/I	S/I	S/I	S/I	S/I	S/I
COVERAGE	BRAIN	TMJ'S	TMJ'S	TMJ'S	TMJ'S	TMJ'S	TMJ'S	TMJ'S
contrast								
comments:								

# Coronal TMJ

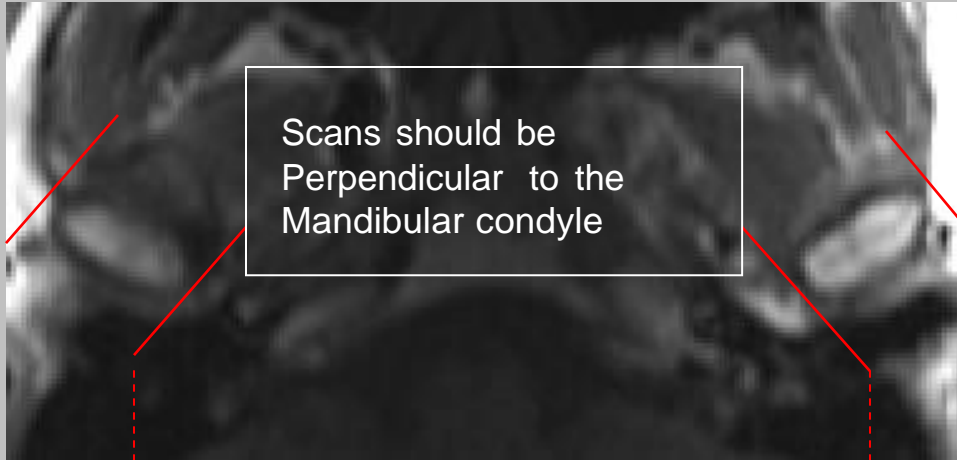


Coronal coverage

A dashed red line with arrowheads at both ends connects the bottom corners of the box in the previous image to this text, indicating the extent of the coronal coverage.



# Sagittal TMJ



Sagittal coverage

A dashed red line with arrowheads at both ends connects the bottom corners of the scan area in the image above to the text "Sagittal coverage".

