

Fundamentals of Breast Tomosynthesis

Improving the Performance of Mammography

Andrew Smith, Ph.D.

This “white paper” is one in a series of research overviews on advanced technologies in women’s healthcare. For copies of other white papers in the series please contact womenshealth@hologic.com

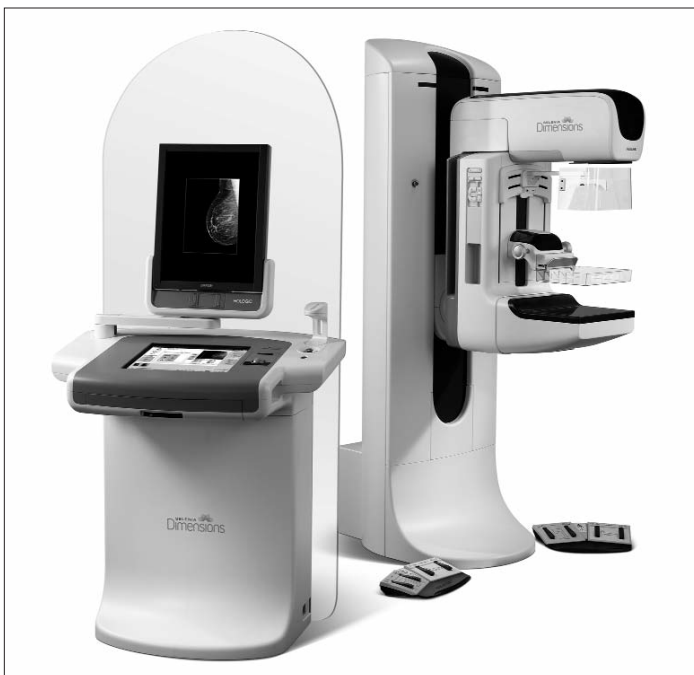Introduction

Breast tomosynthesis is a three-dimensional imaging technology that involves acquiring images of a stationary compressed breast at multiple angles during a short scan. The individual images are then reconstructed into a series of thin high-resolution slices that can be displayed individually or in a dynamic ciné mode.

Reconstructed tomosynthesis slices reduce or eliminate the problems caused by tissue overlap and structure noise in single slice two-dimensional mammography imaging. Digital breast tomosynthesis also offers a number of exciting opportunities including improved diagnostic and screening accuracy, fewer recalls, greater radiologist confidence, and 3D lesion localization.

Hologic has conducted a multi-center, multi-reader clinical trial to measure the clinical performance of tomosynthesis in a screening environment. This paper outlines the theory of tomosynthesis, its expected clinical benefits, and summarizes the results of the clinical trial.

Selenia Dimensions™ Breast Tomosynthesis System*



* Caution. Investigational device in the U.S. FDA clearance pending

Theory of Tomosynthesis

Conventional x-ray mammography is a two-dimensional imaging modality. In conventional mammography, pathologies of interest are sometimes difficult to visualize because of the clutter of signals from objects above and below. This is because the signal detected at a location on the film cassette or digital detector is dependent upon the total attenuation of all the tissues above the location.

Tomosynthesis^{1,2,3,7,8} is a three-dimensional method of imaging that can reduce or eliminate the tissue overlap effect. While stabilizing the breast, images are acquired at a number of different x-ray source angles. Objects at different heights in the breast display differently in the different projections. In Figure 1, two objects (a spiculated lesion and ellipse) superimpose when the x-rays are at 0°, but the off-axis acquisitions shift the objects’ shadows relative to one another in the images.

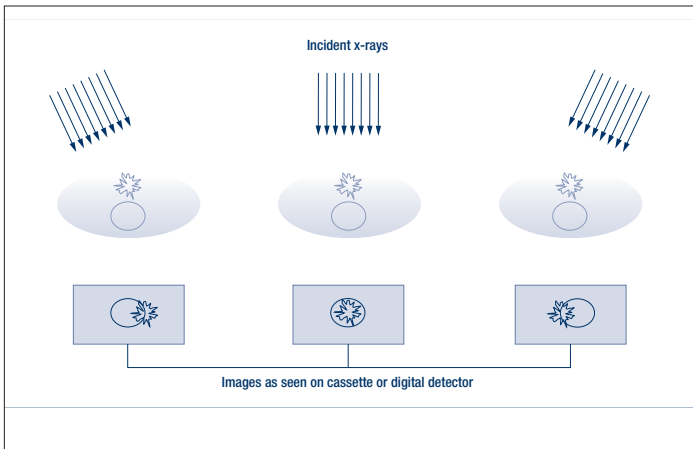
The final step in the tomosynthesis procedure is reconstructing the data to generate images that enhance objects from a given height by appropriate shifting of the projections relative to one another. An example is shown in Figure 2 where we reconstruct a cross sectional slice at one specific height. In this example, the images are summed, shifting one relative to another in a specific way that reinforces the spiculated lesion object and reduces the contrast of the ellipsoidal object by blurring it out.

Note that additional acquisitions are not required to enhance the visibility of objects at any given height—one set of acquired data can be reprocessed to generate the entire 3D volume set.

Performing the Acquisition

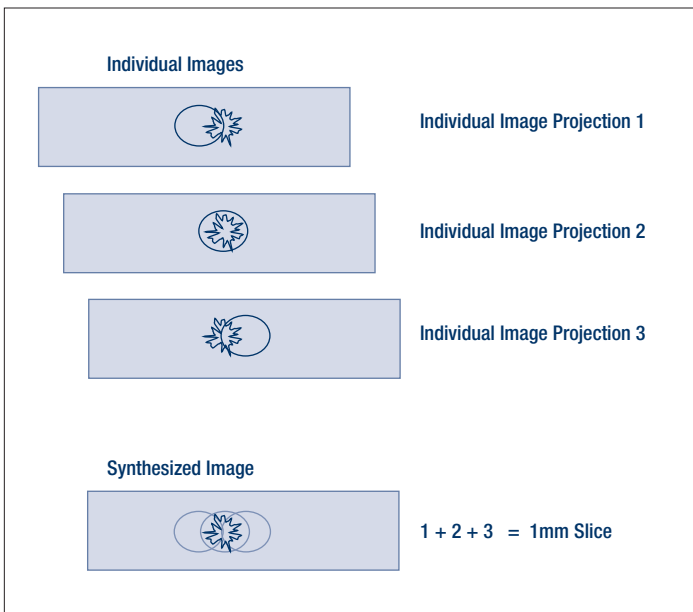
The geometry of tomosynthesis is shown in Figure 3. The breast is compressed in a standard way. While holding the breast stationary, the x-ray tube is rotated over a limited angular range. A series of low dose exposures are made every degree or so, creating a series of digital images. Typically, the tube is rotated through 10-20 degrees and 10-20 exposures are made every 1° or so during a total scan of 5 seconds or less. The individual images are projections through the breast at different angles and these are what are reconstructed into slices.

Figure 1: Tomosynthesis Can Reduce or Eliminate Tissue Overlap



With tomosynthesis imaging, images acquired from different angles separate structures at differing heights. Conventional mammography would acquire only the central image

Figure 2: Tomosynthesis Enhances Objects at a Given Height



By shifting and adding the acquired projections, 3-D imaging increases the visibility of objects by blurring out objects from other heights

Normally the breast would be placed in the MLO or the CC view, although the tomosynthesis system should support the ability to acquire images in any desired orientation.

One consideration in the design of tomosynthesis systems is the motion of the x-ray source during acquisition. The x-ray tube can move in a continuous or step-and-shoot motion. With continuous motion x-ray exposures must be short enough to avoid image blurring due to focal spot motion. If step-and-shoot motion is employed, the gantry must come to a complete stop at each angular location before turning on the x-rays, otherwise vibration will blur the image. The most important criteria is that the total scan time be as short as

Figure 3: Tube Head Swings Taking Multiple Exposures in a Few Seconds



Tomosynthesis acquisition geometry showing the motion of the x-ray source.

possible, to reduce the possibility of patient motion which will degrade the visibility of small microcalcifications and small spiculations.

The angular range and number of exposures acquired during the scan are additional variables that need to be optimized. In general, more exposures will allow reconstructions with fewer artifacts. This must be balanced against the fact that for a given total examination dose, more exposures will mean smaller signals for each of the individual shots. For sufficiently small exposures, imager receptor noise will dominate the image and degrade reconstructed image quality. Increased number of exposures also increase raw data size and reconstruction times. In regards to angular range, a larger angular range gives increased reconstructed slice separation, where smaller angular ranges keep more structures in focus in a given slice. Increased separation theoretically might be desired for resolving two closely lying structures, but could greatly impair the appreciation of a cluster of microcalcifications by having individual calcifications appear in different slices, or the appearance of spiculations lying in more than one narrow plane.

Tomosynthesis System Requirements

Detector Efficiency and Dose

Tomosynthesis imaging consists of a series of low dose exposures, with every acquisition about 5-10% of a normal single-view mammogram. Because each exposure is low dose, it is essential that the image receptor have a high quantum efficiency and low noise. Because images are being acquired at a rate of several images per second, rapid imaging is another

requirement. Selenium-based image receptors, with their high Detective Quantum Efficiency (DQE), greater than 95% x-ray absorption at mammographic energies, and rapid readout capabilities, are an ideal detector for tomosynthesis systems. Using a selenium detector, one is able to perform a tomosynthesis examination with a total radiation dose similar to conventional mammography.

Modes of Acquisition

The tomosynthesis system must be capable of performing all existing 2D digital mammography examinations in addition to the tomosynthesis acquisitions. Tomosynthesis images must be able to be taken in all standard orientations, not just CC and MLO. The system should also be able to take a normal 2D mammogram and the tomosynthesis examination in the same compression. To facilitate this, automated grid retraction is a requirement, so the system can rapidly and automatically switch between 2D and 3D imaging modes.

Image Reconstruction

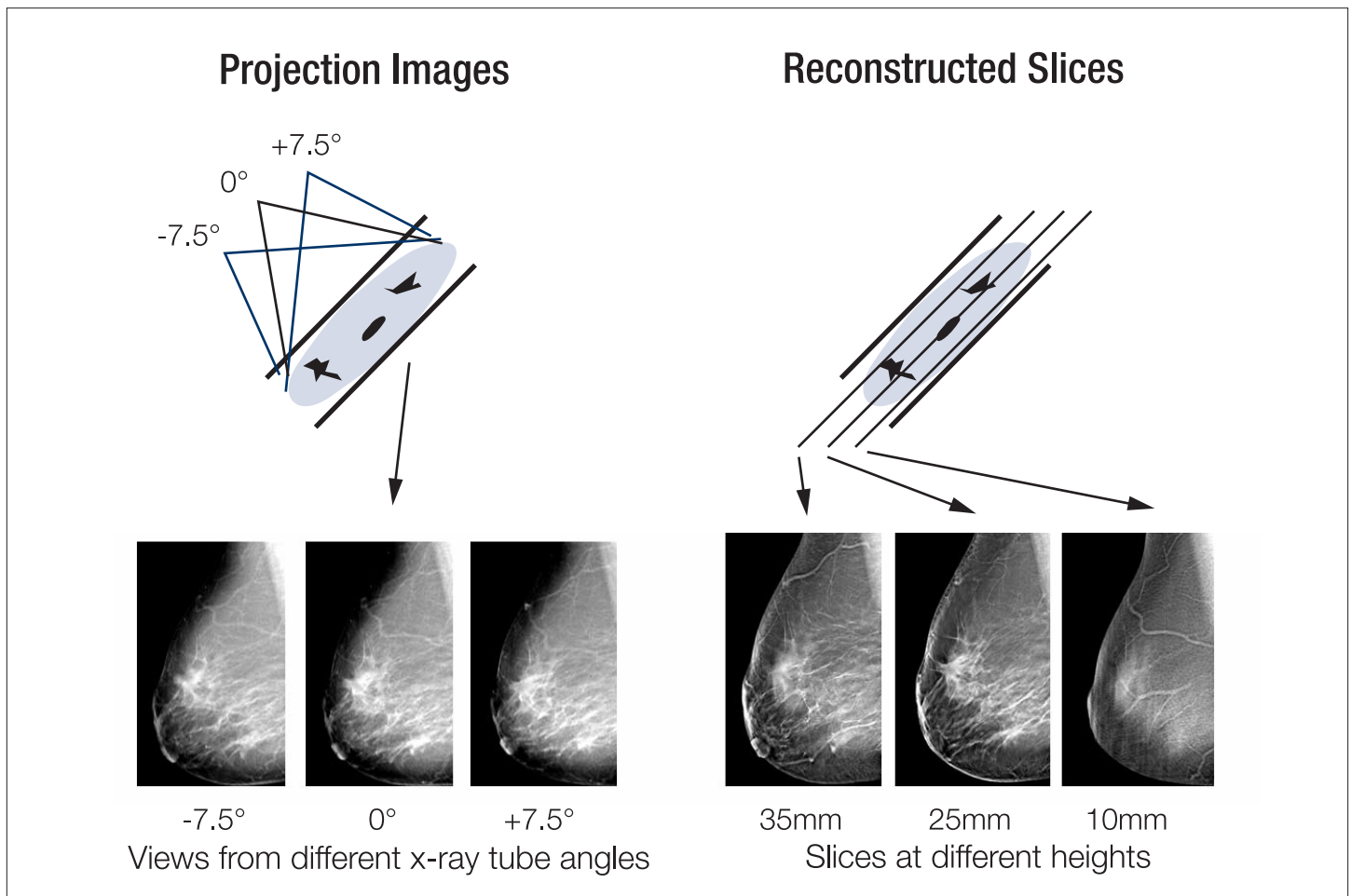
In Figure 4 the tomosynthesis reconstruction process consists of computing high-resolution images whose planes

are parallel to the breast support plates. Typically, these images are reconstructed with slice separation of 1 mm, thus a 5 cm compressed breast tomosynthesis study will have 50 reconstructed slices. Rapid reconstruction time is essential, especially when tomosynthesis is being considered as part of an interventional study, and for this reason it is important to keep post-acquisition processing to 10 seconds or less.

Display Methodology

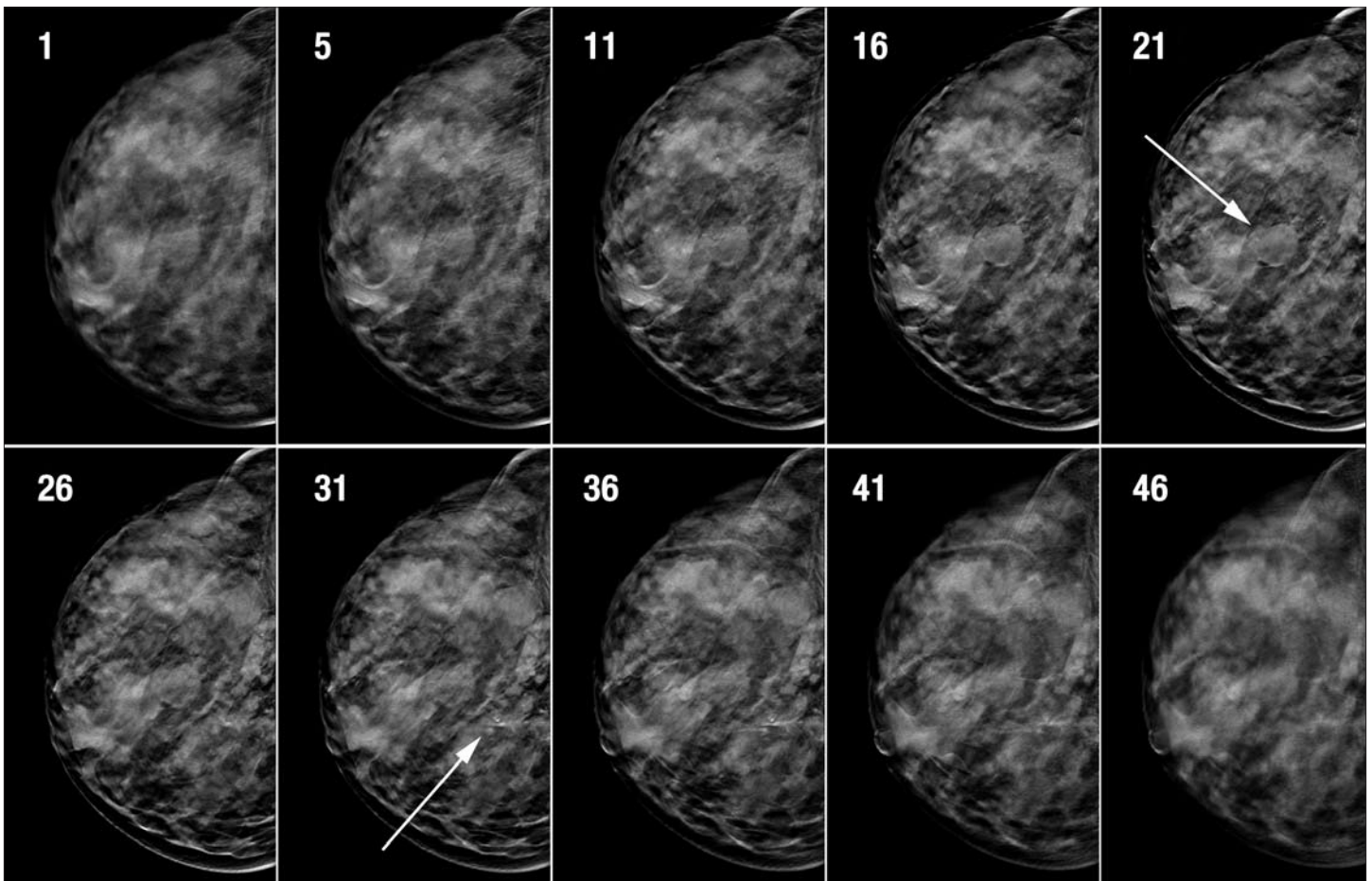
The reconstructed tomosynthesis slices can be displayed similarly to CT reconstructed slices. The operator can view the images one at a time or display them in a ciné loop. The original projections are identical to conventional projection mammograms, albeit each one is very low dose, and these can be viewed as well, if desired. If the system acquired a 2D and a 3D mammogram in the same compression, images from these two modalities are completely co-registered. Workstation user interfaces that allow rapid switching between the two modes will facilitate image review, and allow rapid identification of lesions in one modality with the corresponding lesion in the other modality. Figure 5 shows an example of selected reconstructed tomosynthesis slices in a breast.

Figure 4: Tomosynthesis Takes Multiple Angle Breast Views and Reconstructs Them Into Cross-sectional Slices



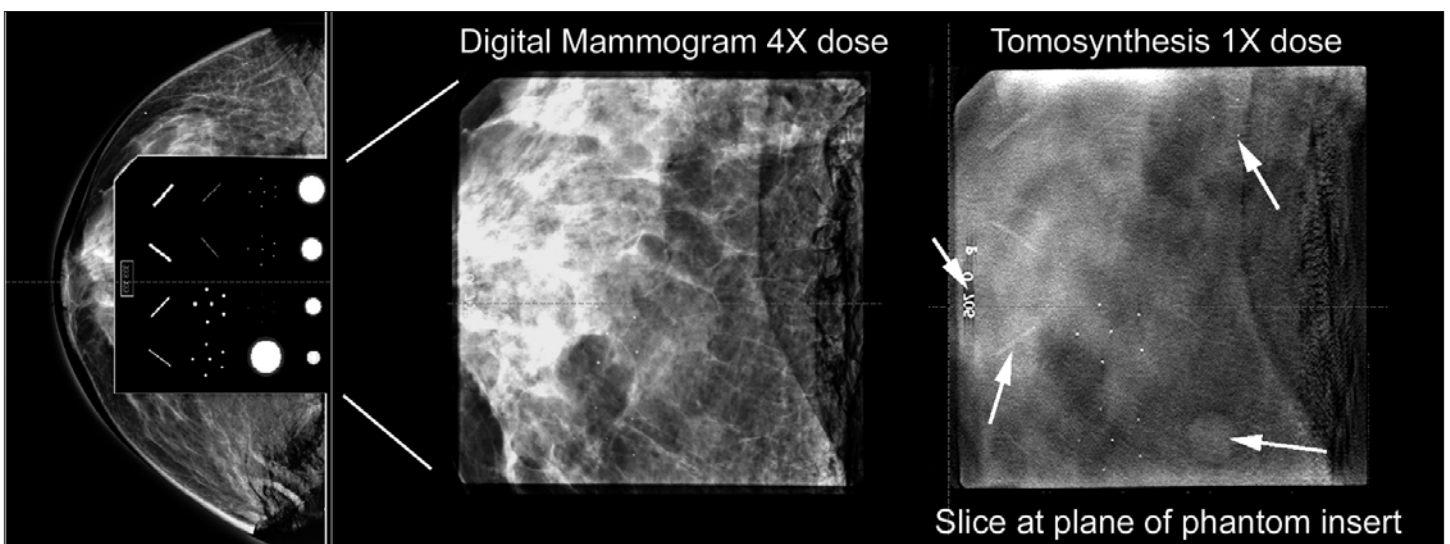
Left image shows three of the 15 projection images acquired through the breast at different angles. Right image shows three of the 1-mm cross-sectional reconstructed slices

Figure 5: Reconstructed Tomosynthesis Slices



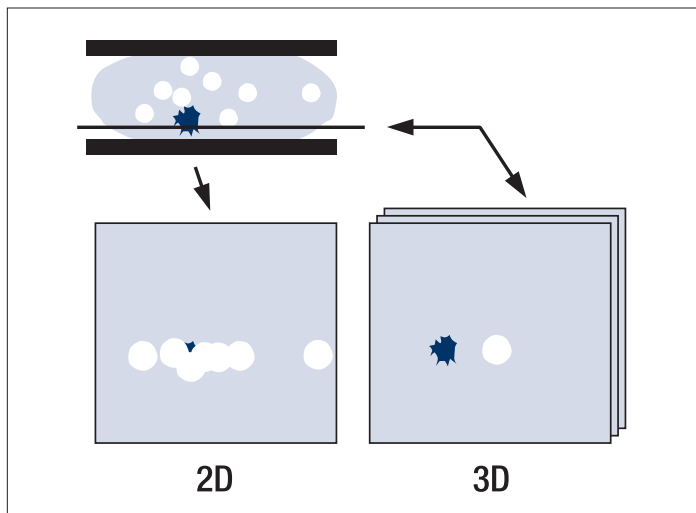
Reconstructed tomosynthesis slices through the breast from breast platform up to compression paddle reveal objects lying at differing heights in the breast, such as cysts and calcifications shown by arrows

Figure 6: Superior Low Contrast Visibility



When the ACR phantom is placed on a cadaver breast and imaged (left), visibility of low contrast objects are reduced. Even at 4x a conventional dose the digital mammogram (middle) shows inferior low contrast visibility to a tomosynthesis image (right) using 1/4 the dose

Figure 7: Tomosynthesis Offers Clearer Images



Tissues that overlap in conventional mammography (left image) and hide pathologies (blue lesion) are less likely to be obscured using tomosynthesis (right image)

Potential Clinical Benefits

Reduced Recalls

Fewer Biopsies

Improved Cancer Detection

Tomosynthesis should resolve many of the tissue overlap reading problems that are a major source of the need for recalls and additional imaging in 2D mammography exams. The biopsy rate might also decrease through improved visualization of suspect objects. Some pathologies that are mammographically occult will be discernable through the elimination of structure noise and tomosynthesis may therefore allow improved detection of cancers.

Tissue Localization

Because the location of a lesion in a tomosynthesis slice completely determines its true 3D coordinate within the breast, biopsy tissue sampling methods can be performed using the tomosynthesis generated coordinates.

Clearer Images

Because the images are presented with reduced tissue overlap and structure noise, objects are expected to be visualized with improved clarity. This will likely lead to more confident readings.

Figure 7 demonstrates why we expect improved confidence with 3D tomosynthesis imaging. In conventional mammography breasts are compressed so as to reduce tissue overlap.

Tomosynthesis is able to provide good visibility of lesions because of the reduction of structure noise. In this figure, the pathology, shown in blue, is obscured in the 2D image from the overlapping tissues shown in white. The appropriate cross-sectional 3D slice, shown on the right, allows clear visualization

of the lesion. The result is improved confidence by the radiologist in their assessments.

One versus two views

In the early development of tomosynthesis it was suggested⁴ that tomosynthesis imaging might only require acquisitions in the MLO view, because the 3D nature of the tomosynthesis images allow viewing the breast from multiple angles. Current indications are that this is not true and that tomosynthesis will require both the MLO and the CC view. This is not surprising, because tomosynthesis differs from other 3D imaging modalities such as CT in that one cannot generate orthogonal multi-planar reconstructions such as sagittal and coronal views from the transverse tomosynthesis image sets. Pathologies that are elongated, planar, or non-spherical in shape may well be better visualized when imaged in one orientation than another. A recent scientific presentation⁶ found that 9% of cancers in their study were seen in the CC tomosynthesis view but not visible in the MLO tomosynthesis view.

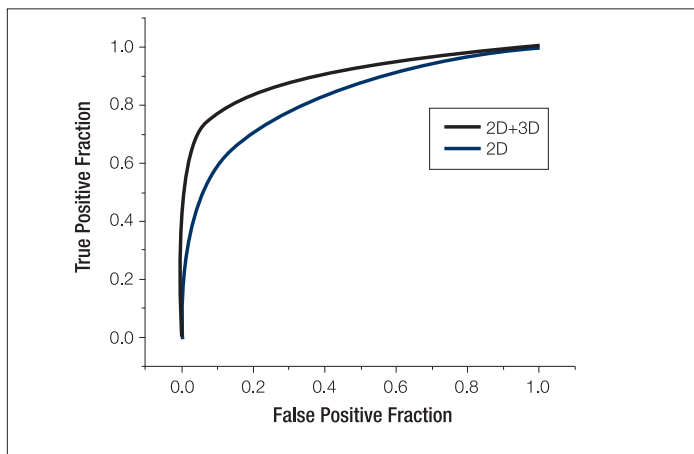
Tomosynthesis Clinical Trials

Hologic has completed a multi-center, multi-reader trial investigating the performance of tomosynthesis.⁵ The purpose of the study was to compare radiologists' cancer detection rate and screening recall rate using conventional digital mammography (2D) plus breast tomosynthesis (3D), to the cancer detection rate and recall rate observed when using 2D alone. In the study, 1,083 women from 5 clinical centers underwent 2D and 3D imaging of both breasts. Cases were collected from a screening population and enriched with patients from diagnostic mammography. Both 2D and 3D imaging consisted of CC and MLO images of both breasts. The CC and MLO 3D images were performed using the Hologic Selenia tomosynthesis prototype.

Three hundred sixteen imaging data sets were randomly chosen to be reviewed by 12 radiologists. The 2D images were scored first, and then the readers reviewed and scored the 2D and 3D exams together. For all 12 readers, clinical performance was superior for 2D plus 3D imaging compared with 2D alone, as measured using the area under the ROC curve.

Figure 8 shows the ROC curve generated from averaging the individual 12 ROC curves. The mean area under the ROC curve for the readers increased from 0.83 to 0.90 using a forced BIRADS scoring, showing an increase of 0.07, a highly significant increase with a p-value of 0.0004. Using 2D plus 3D versus 3D alone, sensitivity, defined as cancers scored as BIRADS 4 & 5, improved from 66% to 76%; specificity, defined as non-cancers with BIRADS scores of 1-3, increased from 84% to 89%; and a mean reduction in the recall rate of 43% was observed. In this multi-center, multi-reader study, radiologist performance improved significantly when using 2D combined with 3D compared with using 2D alone.

Figure 8: Tomosynthesis Improved Performance Compared to Mammography



ROC curves for 2D and for 2D+3D imaging performance, averaged over 12 readers, shows a significant improvement in clinical performance using tomosynthesis

Conclusions

Breast tomosynthesis provides a 3D imaging capability that allows the more accurate evaluation of lesions by enabling better differentiation between overlapping tissues. A lower recall rate, higher positive predictive value for a biopsy recommendation, higher cancer detection rates, fewer recalls, fewer biopsies, and improved radiologist confidence are expected to result from the use of this technology. Breast tomosynthesis should be valuable in both screening mammography and diagnostic mammography.

References

- 1 Dobbins JT III and Godfrey DJ. Digital x-ray tomosynthesis: current state of the art and clinical potential, *Phys. Med. Biol.* 2003 Oct 7; 48(19)R65-106.
- 2 Newman, L. Developing technologies for early detection of breast cancer: a public workshop summary. Washington, D.C.: Institute of Medicine and Commission on Life Sciences National Research Council, 2000.
- 3 Niklason LT, Christian BT, Niklason LE, Kopans DB, et al. Digital tomosynthesis in breast imaging. *Radiology.* 1997 Nov; 205(2): 399-406.
- 4 Rafferty EA, Kopans DW, Wu T, Moore RH. Breast Tomosynthesis: Will a Single View Do? Presented at RSNA 2004, Session SSM02-03 Breast (digital mammography).
- 5 Rafferty EA, Niklason L, Halpern E et al. Assessing Radiologist Performance Using Combined Full-Field Digital Mammography and Breast Tomosynthesis Versus Full-Field Digital Mammography Alone: Results of a Multi-Center, Multi-Reader Trial. Presented at RSNA 2007, Session SSE26-02 Late Breaking Multicenter Clinical Trials.
- 6 Rafferty EA, Niklason L, Jameson-Meehan L. Breast Tomosynthesis: One View or Two? Presented at RSNA 2006, Session SSG01-04 Breast Imaging (digital tomosynthesis.)
- 7 Smith A, Hall PA, Marcello DM. Emerging technologies in breast cancer detection. *Radiology Management.* July-August 2004; 16-27.
- 8 Smith AP, Ren B, DeFreitas K et al. Initial Experience with Selenia Full Field Digital Breast Tomosynthesis. In: Proceedings of IWDM Durham North Carolina, June 2004, Ed. Etta Pisano.

Glossary

| | |
|----------------------|---|
| 2D | Two-dimensional |
| 3D | Three-dimensional |
| BIRADS | B reast I maging R eporting A nd D ata S ystem |
| CC | C ranio C audal |
| Cesium iodide | A radiation detection material used in indirect-conversion x-ray image receptors |
| CT | C omputed T omography |
| DM | D igital M ammography |
| DQE | D etective Q uantum E fficiency. A measure of the dose efficiency of a detector |
| Forced BIRADS | BIRADS scoring allowing values of 1 to 5 only, i.e. no recalls |
| MLO | M ediolateral o blique |
| ROC | R eceiver O perating C haracteristics. A graphical plot of the true positive fraction (sensitivity) vs. false positive fraction (1-specificity) for a binary classifier system as its discrimination threshold is varied |
| Selenium | A radiation detection material used in direct-conversion x-ray image receptors |
| Tomosynthesis | Tomosynthesis combines digital image capture and processing with simple tube/detector motion as used in conventional radiographic tomography. Although there are some similarities to CT, it is a separate technique |

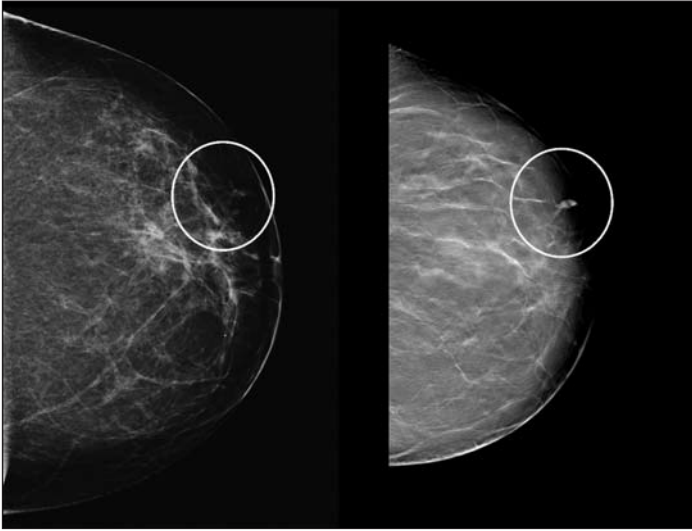
Acknowledgments

I want to thank the following institutions for supplying the images shown here:

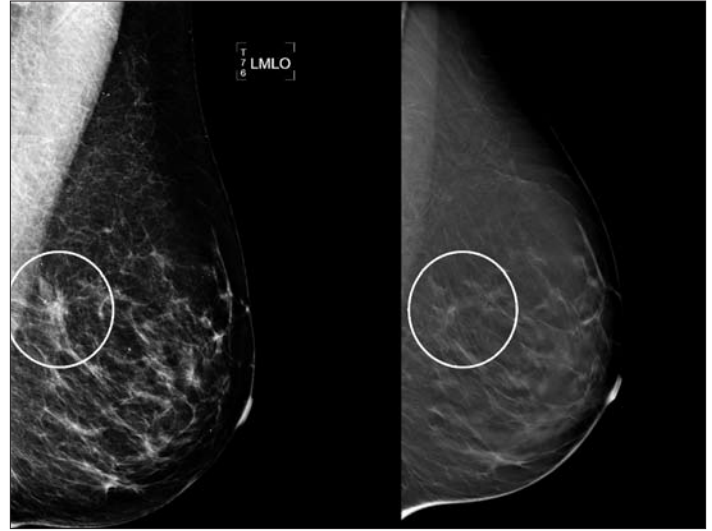
- Dartmouth Hitchcock Medical Center, Lebanon, NH USA
- Magee Women's Hospital, Pittsburgh, PA USA
- Massachusetts General Hospital, Boston, MA USA
- Netherlands Cancer Institute—Antoni Van Leeuwenhoek Hospital, Amsterdam, Holland
- University of Iowa Health Care, Iowa City, IA USA
- Yale University School of Medicine, New Haven, CT USA

Andrew Smith, PhD, is principal scientist at Hologic, Inc. in Bedford, Mass, where he is involved in research and development in digital imaging systems. He attended the Massachusetts Institute of Technology, where he received a bachelor and doctoral degrees in physics.

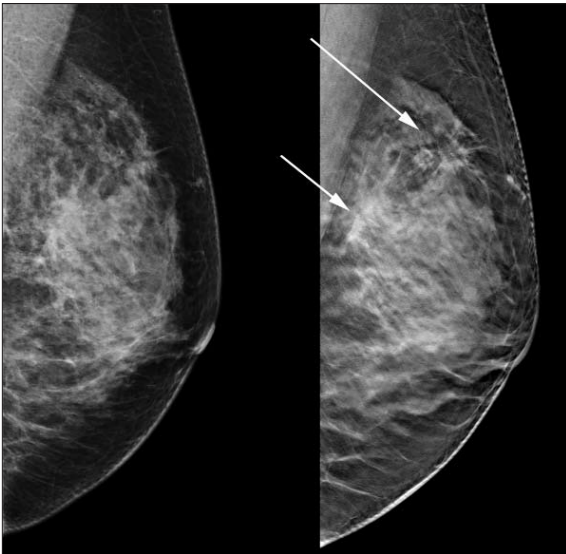
Clinical Examples



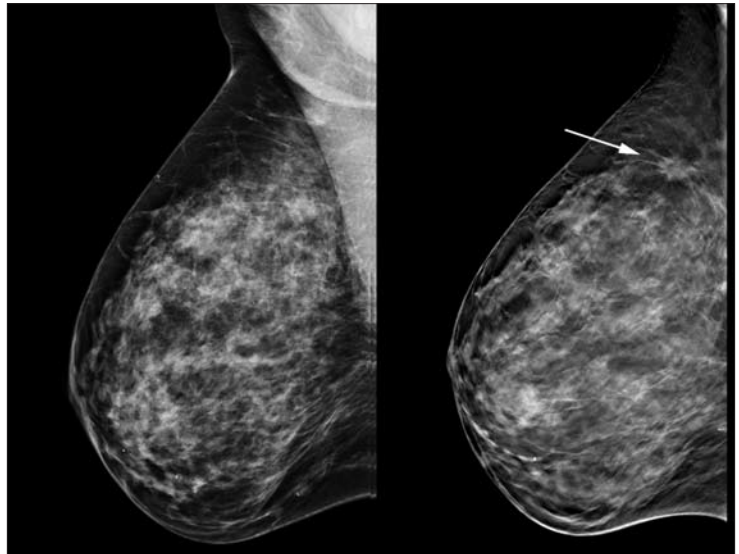
Tubulolobular adenocarcinoma not seen well in the conventional digital mammogram (left image) is much better appreciated in the slice from the tomosynthesis data set (right image)



Suspicious areas in digital mammography (left image) can be resolved with tomosynthesis (right image)



Infiltrating lobular carcinoma and multifocality not seen well in the conventional digital mammogram (left image) are clearer in the slice from the tomosynthesis data set (right image)



Mammographically occult cancers (left image) is visible with tomosynthesis (right image)

Hologic, Inc.
35 Crosby Drive
Bedford, MA 01730 U.S.A.
T: 781.999.7300
www.hologic.com
womenshealth@hologic.com

WP-00007 June 08
