

INFANT HIP ULTRASOUND

With Stress Without Stress

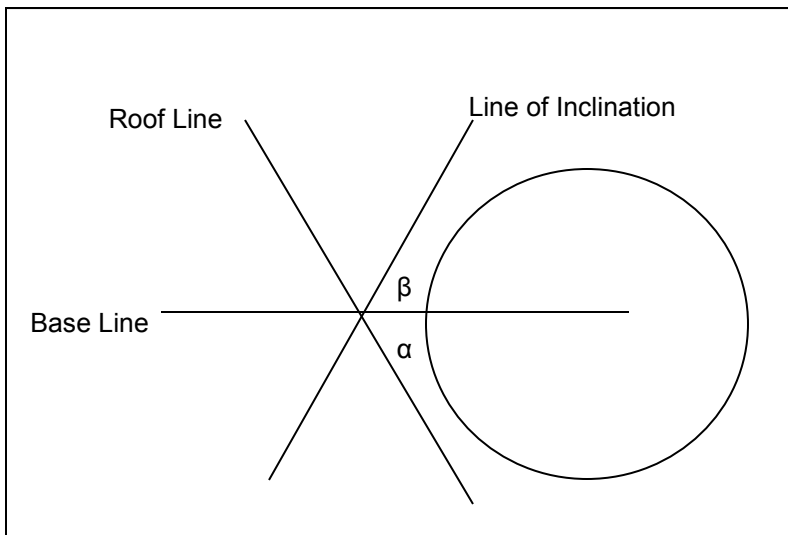
Patient Sticker

Date _____ Ordering _____ Tech _____

Adjusted Gestational Age _____

Indication Hip Click L R Breech Presentation Twin Oligohydramnios
 Hip Dislocation Follow Up; Prior Uls Date: _____

	α	β	FHC	Graf Classification	Stable (with stress maneuver)
Rt Hip	°	°	%		YES / NO
Lt Hip	°	°	%		YES / NO



FHC	Consequences
> 50%	Normal
40-49%	< 4 mos - Possible Dysplasia
40-49%	> 4 mos - Dysplasia
10-39%	Subluxation
< 10%	Dislocation

Graf's Classification	α	β	Consequences
Type 1	> 60°	< 55°	No Therapy
Type 2a	50°-59°	> 55°	< 3 mos - Physiological Immaturity - Follow-up
Type 2b	50°-59°	> 55°	> 3 mos - Treatment
Type 2c	43°-49°	< 77°	Critical Zone
Type 2d	43°-49°	> 77°	Subluxed - labrum everted
Type 3	< 43°	> 77°	Dislocated
Type 4	< 43°	> 77°	Trapped between femoral head and ilium - Treatment