

# SPINAL CANAL ULTRASOUND REPORT

Patient Name

DOB

MRN

Date \_\_\_\_\_ Ordering \_\_\_\_\_ Tech \_\_\_\_\_

Indication

Sacral Dimple

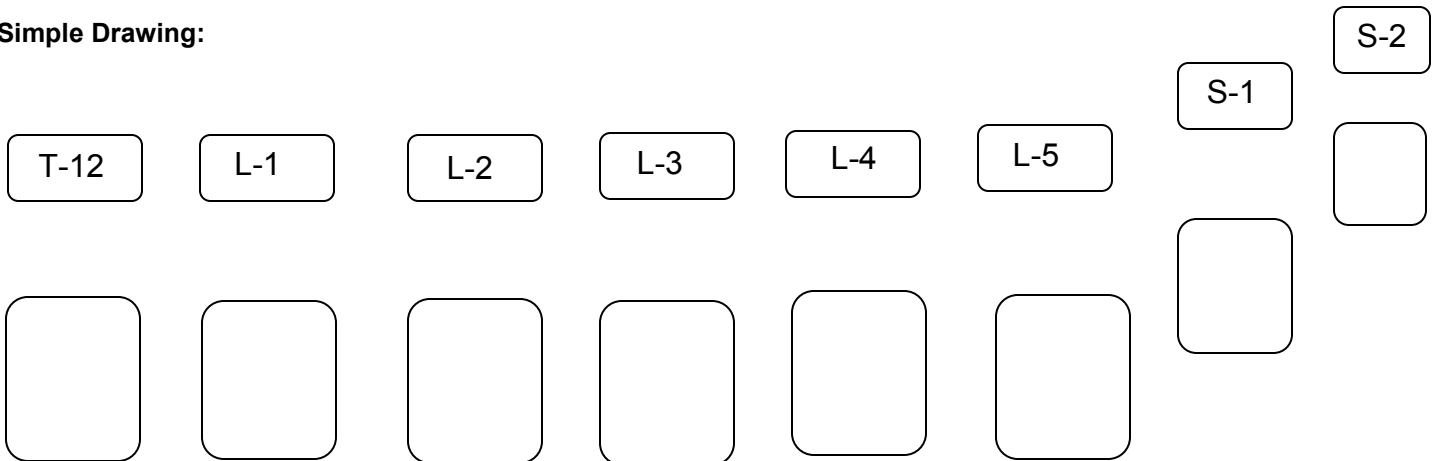
Tuft of Hair

Hemangioma

Lipoma

Other \_\_\_\_\_

## Simple Drawing:



Level of tip of Conus Medullaris: \_\_\_\_\_

Movement of filum terminale identified: Y N

Tethered Cord: Y N

Tract seen at dimple: Y N N/A

Comments: \_\_\_\_\_

\_\_\_\_\_

## Normal Values:

- Conus Medullaris tip resides above L2-L3 disc space
- Movement of spinal cord / filum terminale is evident