

APPENDIX ULTRASOUND

Patient Name _____

Date _____

DOB _____

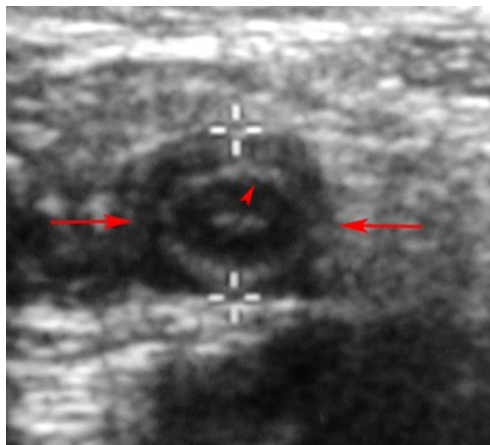
MRN _____

Tech _____

Appendix outer wall thickness _____ mm	<div style="border: 1px solid black; padding: 5px; width: fit-content; margin: auto;"> Appendix Visualized YES NO </div>	
Appendix single wall thickness _____ mm		
Lumen filled with fluid and/or debris? YES NO		
Increase in vascularity of wall?	YES NO	
Patient tender when compressing appendix?	YES NO	
Appendix compressible?	YES NO	
Focal fluid collection seen?	YES NO	

Signs of Appendicitis

1. Outer diameter greater 6 mm (during compression).
2. Lumen filled with fluid and/or debris.
3. Increase in vascularity of wall (or absent blood flow if gangrenous).
4. Non compressible.
5. Single layer of the appendix wall thickness is greater 3 mm.
6. Patient is tender when compressing the appendix.
7. Focal fluid collection (abscess from ruptured appendix, sometimes associated with an appendix that is not seen).
8. Calcified feces (appendicolith) within appendix with shadowing.



Comment:
