

INTUSSUSCEPTION ULTRASOUND

Patient Name _____

DOB _____

Date _____ Tech _____

MRN _____

History: Patient age: _____ Gender: M / F

Indication: Vomiting Bloody Stool Fever Palpable Abdomen Mass

Other _____

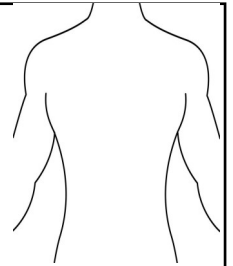
Ultrasound Findings:

Size: _____ x _____ x _____ cm

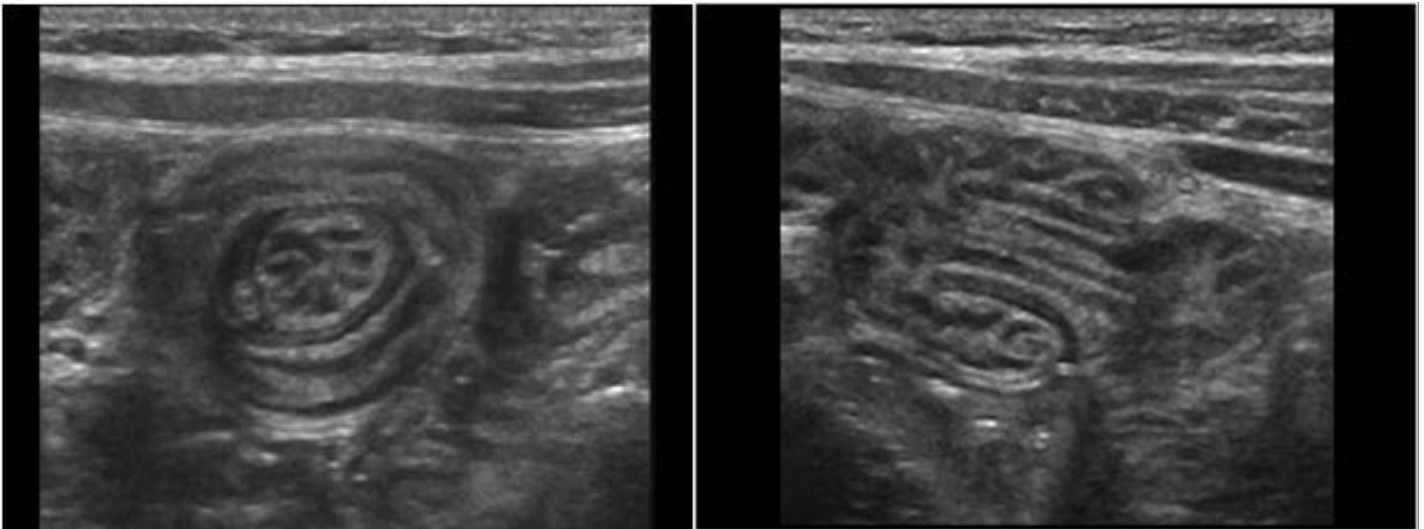
Blood flow noted: YES or NO

Location:

- | | |
|-------------------------------------|-------------------------------------|
| <input type="checkbox"/> RUQ | <input type="checkbox"/> LUQ |
| <input type="checkbox"/> RT MID ABD | <input type="checkbox"/> LT MID ABD |
| <input type="checkbox"/> RLQ | <input type="checkbox"/> LLQ |
| <input type="checkbox"/> PELVIS | <input type="checkbox"/> MIDLINE |



Comments: _____



1. Intussusception occurs when bowel prolapses into more distal bowel.
2. Some symptoms patients may present with are colicky abdomen pain, vomiting and bloody stool.
3. A palpable abdominal mass may be noted.
4. In longitudinal, the mass will appear with an echogenic center with hypoechoic layers on each side.
5. In longitudinal, intussusception can have the appearance of a pseudokidney or sandwich sign.
6. In transverse, the mass will appear as alternating hyperechoic and hyperechoic rings (target sign)

01/2021