



Nuclear Medicine Protocols

	Page
● Index	1
● Bone Scan	2
● Bone Marrow	3 - 4
● Bone Indium	5
● Bone SPECT	6
● Brain Survival	7
● Cisternography	8 - 9
● Gastric Empty	10
● Gastroesophageal Reflux and/or Pulmonary Aspiration	11
● Gastrointestinal Bleeding	12
● Hepatobiliary (HIDA)	13 - 14
● Hepatic Hemangioma Study	15
● Liver Spleen Imaging	16
● Lung Ventilation & Perfusion	17 - 19
● Lymphoscintigraphy	20
● Meckel's Diverticulum	21
● Octreotide Study	22
● Parathyroid Study	23
● Renal Study with and without Lasix	24
● Renal Scan with Vasotec	25
● Thyrogen-Stimulated I-123 Whole Body Scan	26 - 28
● Thyroid Therapy/Ablation	29
● Thyroid Uptake & Scan	30
● Xofigo	31
● Y-90 SirTex	32
● Lymphangiograms (CHN & CHE Surgeons)	33 - 34
● Lymphangiograms (using Lymphoseek®)	35 - 36
● MUGA	37

Bone Scan

Isotope:

^{99m}Tc Medronate (MDP)

Adult Dose:

30 mCi

Indications:

^{99m}Tc MDP may be used as a bone-imaging agent to delineate areas of altered osteogenesis. Indications include:

- Screening of high-risk patients with tumors (e.g. breast, prostate, lung, or kidney) known to metastasize frequently to bone.
- Detection of early osteomyelitis
- Detection of early avascular necrosis
- Detection of stress fractures and other occult skeleton trauma
- Detection and evaluation of Paget's disease, metabolic bone disease, and other osteopathy's
- Detection and evaluation of arthritis and internal joint derangements
- Evaluation of bone viability when blood supply is in question
- Evaluation of bone and joint pain of obscure origin
- Evaluation following an elevated alkaline phosphatase level
- Evaluation following questionably abnormal skeletal radiographs
- Serially following the course of bony response to therapeutic regimens (e.g. radiation therapy, chemotherapy, antibiotic therapy,)
- Diagnosis of reflex sympathetic dystrophy

Bone flow should be obtained if 3 phase bone scan is ordered.

Patient Prep:

- Drink fluids during the 3-hour waiting period.

Exam Time:

- Initial injections: 15 min (Flow if necessary, for 2 minutes, followed by immediate blood pool static image.)
- 3 hour delayed imaging

Equipment and Energy:

- Gamma camera: Dual head, Large field of view
- Energy: 140 keV with a 15% window

Protocol:

- Have patient empty bladder immediately prior to imaging
- Have patient empty all pockets and remove any belt, suspenders, necklace, and metal objects
- Image supine
- Table motion of 10-15 cm/min
- Acquire additional statics as needed. If performing a 3 phase for knee or hip replacement acquire lateral image.

Processing:

- Annotation for image identification, label as necessary, tech initials

Bone Marrow Scan

Isotope:

99mTc Sulfur Colloid

Adult Dose:

10 mCi

Indications:

- Used in conjunction with Bone Scan and/or Bone indium to determine pathologies of the Bone marrow (See attached list for variation on bone imaging)

Patient Prep:

- None

Exam Time:

- Will be part of the patients 2-day bone indium exam

Equipment and Energy:

- Gamma camera: Dual head, large field of view, LEAP parallel whole collimator.
- Energy: 140 keV with a 20% window

Protocol:

- Begin imaging 30 minutes post injection of radiopharmaceutical
- Acquire anterior and posterior images of the area in question

Processing:

- Annotation for image identification, label as necessary, w/tech initials

Note - When doing bone marrow scan in conjunction with bone indium, draw 60cc's of patient's blood first to send to the radiopharmacy to be labeled. Minimum amount to perform exam is 40cc.

Indication/Diagnosis	Appropriate Scan to Order
1. Stress Fracture	1. Three Phase Bone Scan
2. Prosthesis Loosening with <u>NO</u> mention of infection	2. Three Phase Bone Scan
3. Reflex Sympathetic Dystrophy	3. Three Phase Bone Scan
4. Osteomyelitis/Infection a) <u>NO</u> prosthesis or hardware b) <u>NO</u> recent surgery or debridement at site of possible infection	4. Three Phase Bone/ ¹¹¹ IN Scan - 2-day exam with 3 patient visits
5. Osteomyelitis/Infection a.) <u>WITH</u> prosthesis or hardware b) Recent surgery or debridement at site of possible infection	5. Three Phase Bone/ ¹¹¹ IN Scan <u>WITH</u> Bone Marrow Scan 2-day exam with 4 patient visits
6. Osteomyelitis/Infection vs. LOOSENING a.) <u>WITH</u> prosthesis or hardware b) Recent surgery or debridement at site of possible infection	6. Three Phase Bone/ ¹¹¹ IN Scan <u>WITH</u> Bone Marrow Scan 2-day exam with 4 patient visits
7. Charcot Joint	7. Three Phase Bone/ ¹¹¹ IN Scan <u>WITH</u> Bone Marrow Scan 2-day exam with 4 patient visits
8. PARS Defect	8. Bone Spect
9. Spondylolysis	9. Bone Spect
10. Bony Tumor	10. Bone Spect
11. Bone Metastases	11. Bone Scan Whole Body
12. Benign + malignant bone lesions	12. Bone Scan Whole Body
13. Padgett's Disease	13. Bone Scan Whole Body

Bone Indium Scan

Isotope:

Indium-111 labeled White Blood Cells - tagged by radio pharmacy
Tc99mMDP

Adult Dose:

500 uCi In111WBC
30mCi Tc99mMDP

Indications:

- Osteomyelitis
- Infection
- Loosening of prosthetic joint
(See attached list for variation on bone imaging)

Patient Prep:

- None

Exam Time:

- Day one:
 - 1st visit Draw 60cc of patient's blood to send to pharmacy. 40cc minimum
 - 2nd visit re-inject patients' blood that is tagged with Indium-111 and perform bone flow
- Day two
 - 1 visit to perform whole-body and static images

Equipment and Energy:

- Gamma camera: Dual head, Large field of view
- Medium Energy Collimator
- Energy: 171 and 245 keV with a 20% window for Indium
140 keV with a 20% window for Tc

Protocol:

- Whole-body and statics of area of concern

Processing:

- Display Tc99m and IN111 pictures side by side and label them appropriately. Include tech initials

Labeling Procedure: <https://dailymed.nlm.nih.gov/dailymed/fda/fdaDrugXsl.cfm?setid=eacdaf93-c53e-41b6-aebb-7e7d57f5b303&type=display>

- Sterile technique must be used throughout. It is important that all equipment used for the preparation of reagents be thoroughly cleaned to assure the absence of trace metal impurities. The user should wear waterproof gloves during the handling and administration procedure.
- Withdraw from the patient 30-50 ml blood [preferably fifty (50) ml] using aseptic venipuncture technique using the 60 ml syringe fitted with a 19-gauge or 20-gauge needle and containing approximately 1000-1500 units heparin in 1-2 ml. Blood withdrawal should be smooth and slow so as not to produce bubbles or foaming

Bone SPECT

Isotope:

Tc99mMDP

Adult Dose:

30mCi

Indications:

- PARS defect
- Spondylolysis
- To evaluate fractures due to bone trauma

(See attached list for variation on bone imaging)

Patient Prep:

- Drink fluids during the 3-hour waiting period

Exam Time:

- 45 minutes

Equipment and Energy:

- Gamma camera: Dual head, Large field of view
- Energy: 140 keV with a 20% window
- Collimator - LEHR

Protocol:

- Begin imaging 3 hours post injection of radiopharmaceutical
- Have patient empty bladder immediately prior to imaging
- Degree of rotation – 180 x 2 heads = 360 degrees
- Number of images 32 x 2 heads for a total of 64 images
- Time of imaging: 25 seconds/image
- Matrix: 128x128, mode: clockwise
- Patients arms raised above their head

Processing:

- SPECT- Reconstruct transverse, sagittal and coronal images
- Label with tech initials

Brain Survival

Isotope:

Tc99mCeretek

Adult Dose:

30 mCi

Indications:

- Brain Death

Patient Prep

- IV access must be obtained before starting the procedure

Exam Time:

30 minutes

Equipment and Energy:

- Gamma camera: Dual head, Large field of view
- Energy: 140 keV with a 20% window

Protocol:

- Flow taken to establish blood flow to the brain.
- Position patient supine ensuring the entire head is within the field of view.
- Anterior and either lateral image taken at 15 mins post injection

Processing:

- Label all images appropriately and tech initials

Cisternography (CHS Only)

Isotope:

Indium-111 DTPA

Adult Dose:

1.0 mCi or 1.5 mCi

Indications:

- Visualization of flow patterns of spinal fluid
- Detection of CSF leaks
- Evaluation of function of surgical shunts
- Diagnosis of normal pressure hydrocephalus

Patient Prep:

- Informed consent must be obtained before lumbar puncture.

Exam Time:

- Initial lumbar puncture – 30 minutes performed by physician
- Delayed images at 2, 6, and 24 hours post injection – 30 minutes for each set of images
- Images may be needed at 48- and 72-hours post injection

Equipment and Energy:

- Gamma camera: Dual head, Large field of view
- Medium Energy Collimator
- Energy: 171 and 245 keV with a 20% window

Protocol:

- Acquire an immediate spine static after injection
- Acquire a Posterior lumbar spine image at 2 hours
- Acquire Anterior and Left Lateral images at 2, 6, and 24 hours
- Acquire each image for 200 K counts
 - If at 2 hours there are very few counts coming from the head, show the image to the nuclear radiologist to determine if the injection extravasated outside the subarachnoid space. If there has been extravasation, the study is to be terminated.

Processing:

- Label images appropriately including tech initials

Optional Maneuvers:

- Quantitative diagnosis of CSF rhinorrhea:
- 2 hours after intrathecal injection of the radiopharmaceutical, anterior and posterior pledgets are placed in each nostril by an ENT physician.
- Each pledget is approximately 1 cm square, has the absorptive capacity of 0.5 mL of water, has a string attached for removal, and has a label on the string indicating its position.
- 4 hours after placement (6 hours post injection) the pledgets are removed
- 5 mL of venous blood is withdrawn into a heparinized tube at both insertion and removal of pledgets
- 0.5 mL of plasma is withdrawn from each blood sample after centrifugation
- The radioactivity in each pledget and plasma sample is measured in a well counter using a 150-250 keV energy window
- The results are expressed as the ratio of pledget activity over the average plasma activity (See worksheet)
- Normal pledget to plasma radioactivity ratios do not exceed 1.3
- When imaging CSF leaks, obtain ANT, POST, RLAT and LLAT images.
- Position patient in the position that maximizes the leak

- An anterior picture of the abdomen may be taken to look for swallowed radioactive CSF in the intestines
- Cisternography may be used to assess the patency of a lumboperitoneal shunts.
- Acquire serial 1-minute digital images of the abdomen in the RLAT projection for the first 20 minutes after injection
- At 2 hours, acquire ANT and RLAT images of the abdomen
- At 4 and 24 hours, acquire ANT and RLAT images of the abdomen and head

Gastric Emptying

Isotope:

Tc99m Sulfur Colloid

Adult Dose:

2mCi

Indications:

- Diagnosis of functional gastric dysmotility.
- Post-operative changes
- Drug effects

Patient Prep:

- Overnight fast or nothing to eat or drink for 4 hours prior.
- Patient must be off Reglan (Metaclopramide) Zantac, Prevacid, Tums, Phenergan and any other gastric motility meds for 72 hours prior to the exam
- No pain narcotics/pain patches for 48 hours prior to exam
- No laxatives for 24 hours prior to exam

Exam Time:

- Four hours

Equipment and Energy:

- Gamma camera: Dual head, Large field of view
- Energy: 140 keV with a 20% window

Temperature danger zone lies within the range of 40 to 140 degrees. This is prime temperature for bacteria to grow and cause food to be unsafe to consume. Eggs must be cooked to 165 degrees to be at safe serving temperature.

Protocol:

- 120 mL (~4 oz) liquid egg whites mixed with 2mCi of 99mTc Sulfur Colloid should be cooked in the microwave until done. Served with 2 piece of white toast and 30g jelly and 120ml (4oz) of water. Patient should eat the meal in under 10 minutes.
- One-minute images in the anterior and posterior position will be acquired immediately after the meal and at the 1, 2 and 4-hour mark.
- ** If patient has egg allergy, please consult with Radiologist for alternative i.e. Ensure Plus.

Processing:

- Draw regions of interest around the stomach and fill in the counts on the appropriate worksheet which can be found at the end of this manual.
- Enter counts into excel program to get accurate percentage, print page, scan to PACS

Gastroesophageal Reflux and/or Pulmonary Aspiration

Isotope:

- Tc99m Sulfur Colloid

Adult Dose:

- 2 mCi

Indication:

- To determine presence or absence of gastroesophageal reflux and/or pulmonary aspiration.

Patient Prep:

- Overnight fast or nothing to eat or drink for 4 hours prior.
- Patient must be off Reglan (Metaclopramide) Zantac, Prevacid, and Phenergan 72 hours prior to exam
- No narcotics 48 hours prior to exam
- No laxatives 24 hours prior to exam
- Patient should be done in the morning because the gastric emptying time varies with the time of the day.

Exam Time:

- 1 hour

Equipment and Energy:

- Gamma camera: Dual head, Large field of view
- Energy: 140 keV with a 20% window

Protocol:

- 2mCi 99mTc Sulfur Colloid is mixed with 8 oz. of Orange Juice
- 60 min Dynamic image is performed.

Processing:

- Label images and tech initials

Gastrointestinal Bleeding Study

Isotope:

- Tc99m Ultra tag RBC's

Adult Dose:

- 30 mCi

Indications:

- GI bleeding

Patient Prep:

- None

Exam Time:

- 2 hours (30 mins to draw and label blood, and 90 mins of imaging)
- If the bleeding site is identified early on, then the exam can be completed at 45mins-60mins

Equipment and Energy:

- Gamma camera: Dual head, Large field of view
- Energy: 140 keV with a 20% window

Protocol:

- ULTRATAG PREPARATION
 - Draw 1-3cc of patients' blood (Have approx. 0.15 ml of heparin per ml of blood in syringe you are to draw blood with-if using a bottle of heparin that states 100 units/ml)
 - Transfer blood to reaction vial (Using 19 or 21g needle). Gently mix, wait 5 minutes.
 - Add syringe I to reaction vial (syringes are labeled), Gently mix
 - Add syringe II to reaction vial, gently mix
 - Add TCO4- Perchnetate to reaction vial, gently mix, Shield, Wait 20 minutes with periodic mixing. (Should be injected within 30 minutes of preparation.)
 - Mix gently, then draw out blood from the reaction vial and inject. (Use 19 or 21G needle to draw out).
- Image patient supine with the inferior margin of the liver at the top of the field of view.
- Reinject the patient's blood and begin imaging the flow. Perform a 90 min dynamic study. Pt is complete after 90 mins. No delays will be taken. As said above, if the bleed is identified the exam may be ended early.

Processing:

- Label all images appropriately including tech initials

Optional Maneuvers:

- A right lateral at the end of the exam may be beneficial

Hepatobiliary Study (HIDA)

Isotope:

- Tc99m Choletec (Mebrofenin)

Adult Dose:

- 5 mCi

Indications:

- The hepatobiliary study successively demonstrates hepatic perfusion, hepatocyte clearance, hepatic parenchymal transit, and biliary excretion as the radiopharmaceutical moves from the injection site to the intestines.
- Diagnosis of acute cholecystitis
- Evaluation of extrahepatic biliary tract obstruction
- Evaluation of the post-surgical biliary tract
- Detection of bile leaks
- Diagnosis of biliary atresia and other congenital anomalies of the biliary tract

Patient Prep:

- If evaluation of the gallbladder is desired, the patient should have fasted 4 hours. If the patient has fasted for more than 24 hours give 0.02 mcg/kg of Kinevac intravenously over 3-5min diluted in 10ml saline and begin exam.
- The patient must be off pain meds for at least 4 hours prior to this test. Any opiate/Class II Narcotic is included in this screening. These include:
 - Morphine (4 hrs) – Extended Relief Morphine must wait 16 hrs before doing a HIDA scan.
 - Demerol (6 hrs) *Pharmacist reviewed 8/3/2012
 - Oxycontin (4 hrs)
 - Fentanyl (4 hrs) – Duragesic is a brand name for a pain patch containing Fentanyl. These last for 3 days per the Pharmacist. You must wait 16hrs once the patch is removed before doing a HIDA scan.
 - Loritab (4 hrs) PO Med
 - Dilaudid (6 hrs)
 - IV Lipids/ TPN do not interfere with this study.
 - Tube Feedings DO interfere and must be DC'ed for 4hrs pre-scan.

These drugs will restrict the Sphincter of Oddi, preventing Bile from being released into the small bowel.

Exam Time:

- Routine Exam: 60 minutes
- Biliary leak: 90 minutes
- Hepatobiliary Scan with ejection fraction: 90 minutes.

Equipment and Energy:

- Gamma camera: Dual head, Large field of view
- Energy: 140 keV with a 20% window

Protocol:

- Begin imaging immediately after injection of radiopharmaceutical in the anterior position.
- Acquire the following images: ANT imm, 5,10, 15, 20, and 30 min, RTLAT 45 min, and LAO 60 min
- OR
- Dynamic imaging for 60 minutes (60 seconds/frame for 60 frames)

- If the gallbladder has visualized, proceed with ejection fraction:
 - Option 1 (preferred): CCK 0.02 mcg/kg, maximum of 2 mcg) over 30 minutes. Dynamic imaging, 60 seconds a frame for 30 frames (30 minutes total.)
 - Option 2: Boost/Ensure drink over 15 minutes. Dynamic 60 seconds a frame for 30 frames (30 minutes total.)
- **If Outpatient** and there is no GB visualized at 1 hour:
 - Option 1 (preferred): Administer morphine (as below) with 30 minutes imaging. Patient **MUST** have a driver.
 - Option 2: 30 minutes delayed images
- **If Inpatient** and the gallbladder has not been visualized by 60 minutes morphine may be given to rule out acute cholecystitis
- **MORPHINE:** Give 0.04 mg/kg IV not to exceed 4 mg given over 2-3 minutes. To be given only by a nurse or MD. Image for 30 minutes. Take ANT images every 5 minutes beginning immediately after administration of morphine.
- Outpatients cannot drive after administration of morphine; they will need a driver.

Processing:

- CHS Only: Reframe the dynamic images by 5 with an output of 12 images. Load into Hida Flow template and snapshot.
- CHS Only: Snapshot Right lateral with correct annotation.
- ALL: Follow workflow acquisition for processing of gallbladder ejection fraction. I.e. Draw region of interest around gallbladder and draw a small triangle in the liver for background counts.
- Label w tech initials

Hepatic Hemangioma Study

Isotope:

Tc99m Ultra tag RBC's

Adult Dose:

30 mCi

Indications:

- Diagnosis of hepatic hemangiomas – this study depicts the amount of perfusion (early images) and vascular space (delayed images) within the hepatic lesions. Hemangiomas are distinguished by their relatively decreased perfusion and increased vascular volume compared to hepatic parenchyma and most other hepatic lesions.

Patient Prep:

- None

Exam Time:

- 1 hour

Equipment and Energy:

- Gamma camera: Dual head, Large field of view
- Energy: 140 keV with a 20% window
- SPECT software

Protocol:

- Anterior flow
- Static images in the ANT/POST, RAO, LAO, RPO, LPO, and lateral positions for 800k.
- Anterior marker image with the 10cm marker along the costal margin and the 5cm marker in the liver.
- SPECT imaging if requested by ordering MD.
- SPECT imaging at 60 minutes following injection of the radiopharmaceutical.
- SPECT parameters: 360 degrees of rotation, 64 total images, 20 seconds per image.

Processing:

- SPECT image reconstruction: snapshot the transverse, sagittal and coronal images for radiologist to review.
- Label with tech initials

Liver Spleen Imaging

Isotope:

Tc99m Sulfur Colloid

Adult Dose:

5 mCi

Indications:

- Determining the shape of the liver and spleen as well as detecting functional abnormalities of the reticuloendothelial cells of these organs.

Patient Prep:

- None

Exam Time:

- 1 hour

Equipment and Energy:

- Gamma camera: Dual head, Large field of view
- Energy: 140 keV with a 20% window
- SPECT software

Protocol:

- Position patient supine with the upper abdomen in the field of view (include entire liver).
- Image the flow of injection
- Acquire ANT, POST, RAO, LPO, RT LAT, LT LAT, RPO, LAO and ANT Marker static images 15 minutes after initial injection. (1000 kcts per image)
- Use 5 cm marker over liver to measure size and the 10cm marker along the costal margin.
- SPECT imaging may be performed if Radiologist recommends, or requested by ordering MD.
- SPECT parameters: 360 degrees of rotation, 64 total images, 20 seconds per image.

Processing:

- Label images appropriately. Including tech initials
- SPECT image reconstruction: snapshot the transverse, sagittal and coronal images for radiologist to review.

Lung Ventilation and Perfusion

Isotope:

¹³³Xenon Gas for ventilation or Tc^{99m}DTPA aerosol
Tc^{99m} MAA for perfusion

Adult Dose:

6-40 Ci Xenon or 30mCi DTPA
5 mCi MAA

Indications:

Diagnosis of pulmonary embolism; emboli are indicated in the presence of a negative (normal) ventilation scan and a positive (abnormal) perfusion scan.

Patient Prep:

- None

Exam Time:

40 minutes

Equipment and Energy:

- Gamma camera: Dual head, Large field of view
- Energy: 140 keV with a 20% window
- Gas dispenser with return trap and 3-way valve
- Aerosol canister, tubing, O₂

Protocol:

CHS:

- Position patient supine with the lungs within the field of view.
- Acquire a single breath (ventilation) analog image:
 1. Instruct the patient to take a deep breath as the ¹³³ Xenon bolus is injected into the delivery system and then hold the breath for as long as possible.
 2. Start the dynamic acquisition when the patient's lungs are visualized on the P-scope.
 3. After 60 second equilibrate the concentration of ¹³³ Xenon gas within the patient's lungs. Have the patient breath normally for 30 seconds.
 4. Acquire washout analog images by turning the valve to washout so that the patient breathes room air in and exhales the Xenon gas into the system trap.
 5. Close the Xenon delivery system and remove the mask from the patients face.

*If the patient did not get a good 1st breath and equilibrium, repeat the ventilation acquisition outlined above without moving the patient. *

CHN & CHE:

- Hook up O₂ to canister and place mouthpiece in patient's mouth with nose clamp securely in place.
- Turn O₂ up to 15 inject aerosol into tubing and vent patient for a minimum of 5 mins. Instructing them to keep their mouth tight around the mouthpiece.
- After ventilation have the patient lay arms above their head and obtain images in the ant/post, lao, rao, lpo, rpo and lateral positions.

ALL:

- Proceed with the Perfusion portion of the exam.

- Inject patient with 99mTc MAA via IV and acquire 500K images in the ANT and POST, RAO and LPO, RT LAT and LT LAT, and LAO and RPO projections.

Processing:

- Snapshot all images in the workflow for the radiologist to view. Label and include tech initials

Optional Maneuvers:

- Unilateral or regional pulmonary function may be quantitated.

CHS: Shunt Study (for Dr. Mueller):

- Acquire ventilation images
- Set camera for Whole Body acquisition
- Immediately after injection of MAA start whole body protocol
- After whole body imaging acquire the perfusion images of the lung
- Snapshot lung images on templates
- Draw regions around anterior whole body and posterior whole body to get total counts
- Draw rectangular region around lungs on anterior and posterior images to get total lung counts

Perform the following calculations to get the shunt percentage:

Sum Whole body counts – total lung counts

Total whole-body counts

Multiply that number by 100 to get percentage.

- Greater than 15% indicated shunting

CHN SHUNT:

- Following injection of 4mCi Tc99mMAA intrahepatic by the IR doc ant/post 10 min images of each the lungs and liver are obtained. Process using the below excel program.

Calculation of Lung Shunt Fraction

Patient Name:		Date:	
MRN:		IR MD	
Data:	Anterior Liver ROI counts:		
Liver			
	Anterior Liver Background counts:		
	Posterior Liver ROI counts:		
	Post Liver Background counts:		
Data:	Right Anterior Lung counts:		
Lung			
	Left Anterior Lung counts:		
	Ant Lung Background counts:		
	Right Posterior Lung counts:		
	Left Posterior Lung counts:		
	Post Lung Background counts:		
Net Liver Counts:		#NUM!	
Net Lung Counts:		#NUM!	
Shunt fraction:		#NUM!	
Shunt %:		#NUM!	

Lymphoscintigraphy (CHS Protocol)

Isotope:

99mTc Filtered Sulfur Colloid

Adult Dose:

- 1.2 mCi filtered sulfur colloid if injecting the same day of surgery
- 4 - 5 mCi FILTERED if injecting the day before surgery

Indications:

- Identification and localization of draining lymph node groups and sentinel nodes in melanoma and breast cancer.
- Lymphedema

Patient Prep:

- None

Exam Time:

- For breast cancer with no imaging – 15 minutes.
- For Melanoma – 120 minutes.
- For Lymphedema – 75 minutes.

Equipment and Energy:

- Gamma camera: Dual head, Large field of view
- Energy: 140 keV with a 20% window

Protocol:

- Clean area with Chloro-prep
- Radiologist, Radiologist Assistant, Nuclear Medicine will make 4 intradermal injections in the clockwise fashion around the lesion.
- Begin imaging immediately after injection, taking images ANT and Oblique of lesion until tracer has migrated to lymph nodes.
- Acquire transmission image with Cobalt 57 flood source under patient.

Processing:

- Snapshot images and send to PACS for review.
- Requesting physician may want films to take to surgery.

Optional Maneuvers:

- Bilateral Breast Injections order 2.5mCi in 1.2ml. Split dose into 8 syringes, 4 for each breast with a total of 1.0mCi for each breast.
- For lymphedema order 1.25 mCi of 99mTc Filtered Sulfur Colloid
- For lymphedema, inject 500 uCi 99mTc Filtered Sulfur Colloid into each foot (250 uCi between each webbing of toes) the web spaces of each foot between the great toe and the 2nd toe and between the 2nd and 3rd toe. So, a total of 1 mCi is used for this procedure.
- There will be a total of 4 injections.
- Have patient walk around for 30-60 minutes, return and image Whole body with a scan speed of 8cm/min.
- Snapshot and send to Radiologist

Meckel's Diverticulum Study

Isotope:

Tc99m Pertechnetate

Adult Dose:

10 mCi

Indications:

- Detection and localization of a Meckel's diverticulum containing functioning gastric mucosa and other pathologic structures containing gastric mucosa.
- Obscure bleeding

Patient Prep:

- None

Exam Time:

- 60 minutes

Equipment and Energy:

- Gamma camera: Dual head, Large field of view
- Energy: 140 keV with a 20% window

Protocol

- Lay the patient supine with the camera over the abdomen. The right side of the patient should be elevated with a small wedge or pillow to keep secretions within the stomach.
- A 2 sec/frame dynamic flow is done for 120 seconds
- An immediate anterior image is taken following the flow. Images at 5, 10, 15, 20, 30, 45, and 60 mins are taken.
- It is possible to do a dynamic study for 60 sec/frame for 60 mins.

Processing:

- Snapshot images and send to PACS for review, and label with tech initials.

Octreotide Study

Isotope:

¹¹¹Indium Pentetreotide

Adult Dose:

6 mCi

Indications:

- Scintigraphy localization of primary and metastatic neuroendocrine tumors bearing somatostatin receptors. Included are carcinoid, islet cell carcinoma, gastrinoma, insulinoma, VIPoma, motilinoma, medullary thyroid carcinoma, neuroblastoma, paraganglioma, pheochromocytoma, pituitary adenoma, meningioma, small cell lung carcinoma, and undifferentiated APUDoma.

Patient Prep:

- Bowel prep is required prior to octreoscan. Patient should start a mild over the counter laxative the morning of day 1 and continue throughout the 48 hours of the exam.
- Ample fluid intake is necessary during the period of imaging as a support to renal elimination and the bowel cleansing process.

Precautions:

- **Insulinoma patients:** Octreoscan may produce severe hypoglycemia in patients with insulinoma. An IV solution containing glucose should be administered just before and during Octreoscan administration.

- **Concurrent Octreotide Therapy:** Sensitivity of Octreoscan imaging is reduced in patients receiving therapeutic doses of Octreotide acetate. **Octreotide therapy must be discontinued 72 hours before administration.**

Exam Time:

- Injection- 15 minutes
- 4 HR images: 30 minutes, whole-body only
- 24 HR images: 1 hour, whole-body and SPECT
- 48 HR images: 1 hour, whole-body and SPECT (most patients are done imaging at this point. Check with Rad)
- 72 HR images: 1 hour, whole-body and SPECT (only performed if requested by Rad)

Equipment and Energy:

- Gamma camera: Dual head, Large field of view
- Medium Energy Collimator
- Energy: 171 and 245 keV with a 20% window

Protocol:

- Whole-body images at 4, 24, and 48 hours
- SPECT the abdomen to include the liver during the 24 and 48 HR images. 128 x 128 matrix with at least 40 sec/stop.

Processing:

- Snapshot images and send to PACS for review. Include tech initials

Parathyroid Study

Isotope:

Tc99m Sestamibi

Adult Dose:

25 mCi

Indications:

- Detects and localizes parathyroid adenomas.

Patient Prep:

- None

Exam Time:

- Initially 45 mins
- Delayed imaging at 3 hours: 20 minutes

Equipment and Energy:

- Gamma camera: Dual head, Large field of view
- Energy: 140 keV with a 20% window

Protocol:

- Lie patient supine on table with head at the top of the pillow so the neck is extended
- Inject patient and wait 10 mins.
- Position the patient under the camera so the tip of the heart is at the bottom of the field of view
- Take anterior, lao and rao images at 10 mins post injection.
- After initial static images a SPECT is performed on all patients
- Patient will return 3 hours later to retake the anterior, lao, and rao static images.

Processing:

- Label images and send to PACS for review. Including tech initials

Renal Study w/and w/out Lasix

Isotope:

Tc99m MAG 3

Adult Dose:

5 mCi

40mg Lasix for adults, 0.5mg/kg for children

Indications:

- Chronic renal failure, obstruction, hypertension, infection, hematoma, trauma

Patient Prep:

- Patient should be well hydrated and should void before the exam.
- No Lasix 24 hours prior to the start of the exam
- If the patient has any sort of drain or Foley in place discuss with the Rad to see if it should be clamped shut

Exam Time:

- 45 minutes

Equipment and Energy:

- Gamma camera: Dual head, Large field of view
- Energy: 140 keV with a 20% window

Protocol:

- Position patient supine with pelvis in the bottom field of view and xiphoid process in the top field of view
- Set up IV and inject
- A dynamic flow is obtained during injection
- NO LASIX: 60 sec/frame images are taken immediately following the flow for a total of 30 mins.
- LASIX: 60 sec/frame images are taken immediately following the flow for a total of 41 mins.
 - Inject the 40mg Lasix over a 3 min time span at 20 minutes after injection of MAG3.
 - Try to continue the Lasix images for at least 20 mins post Lasix injection. Have the patient hold it as long as possible.
 - The patient should void when exam ends and obtain a 60 sec post void static image.

*any patient with a diagnosis on kidney stones will automatically be a renal with Lasix study.

Processing:

- Draw regions of interest around each kidney with backgrounds.
- Mark the time Lasix was given on the graph
- Check graphs and data for accuracy
- Snapshot and send images to PACS for review. Include tech initials

Optional Maneuvers:

- For transplant kidney, image in the ANT projection

Renal Scan w/Vasotec

Isotope:

Tc99m MAG 3

Adult Dose:

2 mCi baseline

8 mCi post vaso study

20mg Lasix

0.04mg/Kg of Vasotec not to exceed 2.5mg (diluted in 10cc saline)

Indications:

- Renal Artery Stenosis, neurovascular hypertension

Patient Prep:

- Patient needs to be off ALL Ace inhibitors for 48 hours prior
- Patient needs to be off ALL blood pressure meds for 24 hours prior
- Patient needs to be off Lasix for 24 hours prior
- Patient should be very well hydrated
- Patient should empty their bladder immediately prior to exam

Exam Time:

- 90 minutes

Equipment and Energy:

- Gamma camera: Dual head, Large field of view
- Energy: 140 keV with a 20% window

Protocol:

- Position patient supine with pelvis in the bottom field of view and xiphoid process in the top field of view
- Set up IV
- Inject the 2 mCi dose of Mag3 and begin flow
- 60 second images are obtained for 30 mins immediately following the flow
- The patient's blood pressure should be taken at the end of the first set of images. Patients BP needs to be above 140. Inform radiologist if this is not the case.
- Patient should empty bladder and lie back down on the table
- Inject the diluted Vasotec IV at a rate of 0.5mg/minute
- BP's should be taken every 5 minutes for the remainder of the exam and recorded
- 10 minutes post injection of Vasotec position the patient under the camera and begin the second set of images. Inject with the 8mCi dose of Tc99mMAG3.
- At 3 mins into the study 20mg Lasix is injected over a 3 min time span
- The study should run at minimum 20 mins post Lasix injection or until the patient asks to stop due to inability to hold bladder.
- Have the patient void and take a 1-minute post void image

Processing:

- Draw regions of interest around each kidney with backgrounds.
- Process both the pre and post vasotec scans with the protocol on the camera
- Mark the time Lasix was given on the graph
- Check graphs and data for accuracy
- Snapshot and send images to PACS for review. Include tech initials

Thyrogen-Stimulated I-123 Whole Body Scan

See Thyrogen Flowsheet

*** All thyroid whole-body scans, thyrogen whole body scans, therapies, and ablations MUST be schedule between the Nuc Med dept and the ordering doctors off. All proper paperwork will be filled out and completed by NM staff. NM staff will then call central scheduling with dates and times for the appropriate exams.**

Isotope:

Sodium Iodine I-123

Adult Dose: Order from ROI

3 mCi I-123 oral capsule

100 uCi standard

Indications:

- Evaluates functional thyroid tissue following thyroidectomy for thyroid cancer
- I-131 ablation in patients unable to tolerate thyroid hormone withdrawal

Patient Prep:

- 3-day exam
- Patient can stay on thyroid medications throughout entire study
- Patient must be NPO 4 hours prior to taking the I123 pill on the second day, and NPO 1 hour after.

Exam Time:

- Day 1- 15-20 minutes
- Day 2- 10-15 minutes
- Day 2- 15 minutes
- Day 3- 60 minutes

Equipment and Energy:

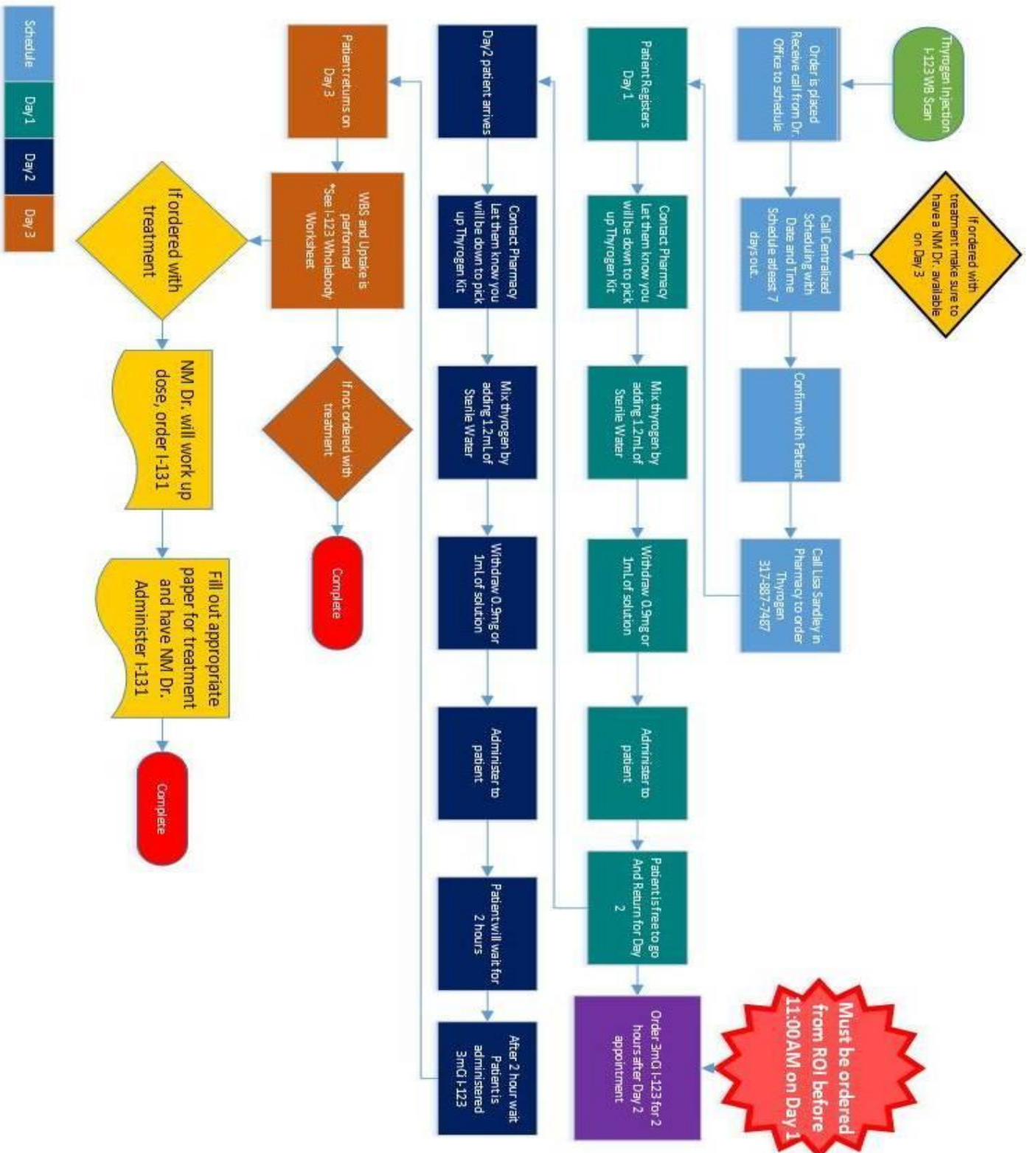
- Gamma camera: Dual head, Large field of view
- Collimator: LEHR
- Energy: 159 keV with a 20% window

Protocol:

- Day 1 -Thyrogen injection #1 by nursing staff
- Day 2 -Thyrogen injection #2 by nursing staff
- Day 2 - 2 hours after Thyrogen the patient returns to take the I-123 3 mCi oral capsule
- Day 3 -24-hour whole body I-123 scan and uptake
- Uptake: use manual mode on Uptake Probe, Count Standard 3 x 1 minute, Count Background 1 x 1 minute, Count Patient Thyroid 3 x 1-minute, Patient Background 1 x 1 minute, be sure to print counts after each 1 min count. Fill out I-123 Whole-body worksheet and calculate uptake.

Processing:

- Process as a Thyroid WBS
- Label accordingly
- If desired take an extra anterior or pinhole of the patient's neck
- Snapshot all images and record patient's thyroid uptake on images, send to PACS for review.



Schedule Day 1 Day 2 Day 3

I-123 WHOLEBODY WORKSHEET

Tech: _____

Date: _____

		STD CNTS	PT CNTS
PT DOSE uCi			
STD DOSE uCi			
		-/- 3	-/- 3
	TOTAL		
	-BKG		
	TOTAL CNTS		

$$\% \text{ UPTAKE} = \frac{\text{PT CNTS}}{\text{STD CNTS} \times \frac{\text{PT DOSE}}{\text{STD DOSE}}} \times 100$$

$$\% \text{ UPTAKE} = \frac{\quad}{(\quad) \times (\quad)} \times 100 = \quad \%$$

Thyroid Therapy (hyperthyroid)/Ablation (thyroid cancer)

*** All thyroid whole-body scans, thyrogen whole body scans, therapies, and ablations MUST be schedule between the Nuc Med dept and the ordering doctors off. All proper paperwork will be filled out and completed by NM staff. NM staff will then call central scheduling with dates and times for the appropriate exams.**

Isotope:

I-131 Sodium Iodine

Dose:

Calculated by Nuclear Medicine Physician after Patient has had an Uptake and Scan or thyroid whole body/thyrogen whole body/thyrogen injections only.

Indications:

Treatment of benign or malignant conditions of the thyroid gland.

- Hyperthyroidism
- Nontoxic multinodular goiter
- Thyroid Cancer

Patient Prep: (Written Directive, Consent, and Instruction are in File Cabinet)

- Patient must discontinue Thyroid Medication. Unless Patient received Thyrogen Injections.
- Low Iodine diet if requested for 2 weeks prior for ablation (provided by ordering doctor's office)
- TSH, T3, T4, Labs drawn, and results printed
- Previous recent Uptake and Scan/imaging
- Beta HCG (Pregnancy Test) drawn and results printed: Under the Age of 50
- Pathology reports printed and entered in patients file
- Patient must be 6 weeks post thyroidectomy to have an ablation performed
- If no thyrogen is given TSH must be above 30

Exam Time:

30 Minutes

Equipment:

Dose Calibrator

Protocol:

- Labs, Uptake, Scan, and Written Directive given to Nuclear Medicine Physician to prescribe a dose. (Dose must be written on written directive and signed and dated by prescribing Nuclear Medicine Physician)
- Order prescribed Dose
- Technologist must perform 2 pt. ID with any of the following: Name, DOB, Driver's License
- Nuclear Medicine Physician explains therapy/ablation to patient and gives patient restrictions
- Patient Signs Consent
- Dose is measured in the dose calibrator
- Patient release calculation is performed PRIOR to dosing patient, printed and entered into file
- Dose is Administered
- Instruct Patient not to eat anything for 1 hour
- ALL patients will return for a 7-day post ablation scan IF for thyroid cancer.

Processing:

- Scan paperwork into PACS and Originals placed in Folder and put in file Cabinet

Thyroid Uptake and Scan Study

Isotope:

- I123 Sodium Iodide

Adult Dose:

- 200 uCi I123 pill (formulary range 200-300, but order 200 uCi)

Indications:

- The thyroid imaging study with radioiodine demonstrates the distribution of functioning thyroid tissue, including ectopic tissue, since thyroid tissue is the only tissue that concentrates large amount of iodine.
- Evaluation of palpable nodules, abnormal thyroid gland, ectopic thyroid tissue, congenital hypothyroidism, abnormal thyroid lab work, hyperthyroidism, Graves, Thyroid Storm

Patient Prep:

- Patient must be off Synthroid x 6 weeks, PTU x 3 days, Armour x 2 weeks, Tapazol (methimazole) x 3 days, Cytomel x 2 weeks (see list)
- No intravenous or intrathecal iodinated contrast material for at least 6 weeks.
- Patient needs to be NPO 4 hours prior to the administration of the I123 pill and NPO for 1-hour post administration.

Exam Time:

- Initially: Dose administration is 10 minutes
- 24-hour delay imaging: 45 minutes

Equipment and Energy:

- Gamma camera: Pinhole collimator if available, or LEHR collimator: Energy: 159 keV with 15% window width

Protocol:

- **Day 1:** Count the capsule in the uptake probe and take a room background. Save to thyroid probe.
- Make sure patient has been off all meds, has had no Contrast, is not pregnant or breastfeeding and proceed with dosing the patient.
- **Day 2:** Begin with 2 uptake counts on the thyroid probe. We do this twice so we can average them out. You want each uptake percent to be within 5% of each other. Record these numbers of requisition.
 - Option 1 - Using the Pinhole collimator position the patient's thyroid in the middle of the field of view.
 - **Images taken with pinhole collimator:**
 1. Distance with the pinhole away from the patient to include salivary glands and mediastinum
 2. Pull pinhole within 4 fingers width of the patient's neck. Take anterior image.
 3. Marker image w/ 5cm marker on the patient's neck vertically in the middle of the thyroid.
 4. LAO @ 30 degrees
 5. RAO @ 30 degreesAll images should be taken for 120K. or 10 minutes.
 - **Images taken with LEHR collimator**
 1. Take anterior image.
 2. Mark anterior image with 5-10 cm marker and SSN marker on the patient's neck.
 3. LAO @ 30 degrees
 4. RAO @ 30 degrees
 5. All images should be taken for 10 minutes or 50K.

Processing:

- Snapshot all images, record patient's thyroid uptake on images, include tech initials, and send to PACS

Xofigo

Isotope:

Radium 223

Dose:

Calculated by Xofigo Pharmacy based on weight

Indications:

Castration Resistant Prostate Cancer with symptomatic bone metastases

Patient Prep:

None

Exam Time:

30 Minutes

Equipment:

- Dose Calibrator
- Personal Protective Equipment

Protocol:

- Radiation Oncology will call with date and time to schedule
- Radiation Oncology will order dose, once dose is ordered have Radiation Oncology fax over Written Directive with Radiation Oncologists Signature and date
- Once dose is received and checked in, measure dose and insert information of initial assay into the Xofigo Excel Worksheet on Computer. (Initial Assay Upon Receipt)
- Radiation Oncology Nurse will obtain IV and Vitals
- Radiation Oncologist should wear PPE equipment (Gown and Shoe covers)
- Radiation Oncologist will administer dose over 1 minute, using a three way stop cock flush the syringe and IV with 30mL of Normal Saline
- Measure Syringe for residual, insert information from assay into the Xofigo Excel Worksheet (Calculation Post Injection)
- Using information from Xofigo Excel Worksheet fill out remainder of the written directive.
- Survey Patient 10 cm from umbilicus and Room, record on Written Directive
- Obtain Radiation Oncologist Signature on completed Written Directive
- Make 2 copies of Written Directive for Radiation Oncology Nurse and to be scanned into PACS
- Place Original in folder and file in File Cabinet under Xofigo

Y-90 SirTex

Isotope:

Yttrium 90

Dose:

Calculated by RSO and Administering MD

Indications:

Treatment of unresectable metastatic liver tumors from primary colorectal cancer with adjuvant intra-hepatic artery chemotherapy

Patient Prep:

Given by IR nurse

Exam Time:

IR: 1-2 hours

NM: 30 mins

Equipment:

- Dose Calibrator
- Gamma Camera
- Acrylic Shield and syringe shield
- Venting needles
- Dextrose
- Absorbent paper
- drawing supplies that comes with dose provided by Sirtex

Protocol:

- IR Nurse will schedule mapping and procedure; they will email RSO to confirm date
- Once date is confirmed and orders are entered, schedule on NM work list

Treatment

- RSO will be present for the drawing of the dose.
- follow drawing guidelines provided by the company insert

Images performed

- Collimators MELP
- Tomo- 20 sec/frame
- around the liver
- set analyzer to Bremstrahlung
- Review and add tech initials, and send to Pacs

Lymphangiograms (CHN & CHE Breast Surgeons)

Isotope:

Tc99mSC (unfiltered ordered)

Adult Dose:

Dependent on the Surgeons preference. See below.

Dr. Goedde, Dr. Nate, Dr. Goulet & Dr. Kim:

Normal: 1.2mCi Tc99m filtered sulfur colloid in 1.5mL saline. Add 2mL lidocaine with a long 25g needle, if requested by surgeon.

Melanoma style: 1/2mCi Tc99mSC in 0.5mL saline. Divide into 2 syringes w/ 30 g needle.

Bilateral breast injections order one normal dose per breast

**Technologist will inject Dr. Goedde's patients.

Dr. Nate, Dr. Goulet, and Dr. Kim's doses will be delivered to the surgery center for injection in surgery by the surgeon**

Dr. Wagner:

1.0mCi Tc99mSC in 0.2mL saline divided into 2 syringes w/ a 30g needle. (Extremities/head)

1.0mCi Tc99mSC Filtered in 0.2mL saline divided into 2 syringes w/ a 30g needle (trunk and reinjections)

5.0mCi Tc99mSC in 1.0mL: this dose will be filtered by the tech for any reinjections or trunk injections. Once filtered this will be used for the above 1.0mCi filtered injections.

Lymph edema:

2.0mCi Tc99mSC in 1.0mL saline. Divided into 4 syringes w 30g needle

Indications:

- Identification and localization of draining lymph node groups and sentinel nodes in melanoma and breast cancer.
- Lymphedema

Patient Prep:

- None

Exam Time:

- For breast cancer with no imaging – 10 minutes
- For Melanoma – 60-120 minutes.
- For Lymphedema – 75 minutes.

Equipment and Energy:

- Gamma camera: Dual head, Large field of view
- Energy: 140 keV with a 20% window

Protocol:

- Breast injection using Tc99mSC is injected by the tech into the subcutaneous tissue subareolar in the breast. There is no imaging for any breast injection.

- Melanoma injections are done intradermal around the melanoma site by the technologist. The injections will be spaced evenly at either the 3 and 9 o'clock position or the 12 and 6 o'clock position.
- **Images:** should begin immediately after injection. Images should be done every 5 mins lasting 60 seconds.
 - Back-axilla, groin, and neck
 - Legs-pelvis and posterior knees
 - Arms-axilla, neck, elbow
- If there is no lymph node showing at 30 mins then REINJECT, the patient 1.0mCi Filtered SC.
- Throughout the imaging take transmission films with the cobalt sheet source to outline the body.
- Mark the patient's skin where the sentinel lymph node is on film with surgical marker at the end of the exam
- Lymph edema injections should be placed into two web spaces on either foot. This is done by the technologist.
 - **Images:** should begin immediately after injection with images of the feet, knees and pelvis for 2 mins each. Repeat images at 30 mins and 60 mins post injection.

Processing:

- Snapshot images and send to PACS for review.
- Process lymph edema with the attached worksheet and scan into PACS

Lymphangiograms (using Lymphoseek®)

Isotope and Radiopharmaceutical:

Tc-99m tilmanocept (Lymphoseek®)

Adult Dose Range (breast lymph node mapping):

0.4 – 1.3 mCi in 0.1 cc

Adult Dose Range (melanoma):

0.5 mCi per injection in 0.1 cc (2 or 4 syringes/injections total, based on physician preference)

NOTE: Addition of lidocaine is **NOT** recommended for this drug.

Indications:

- Identification and localization of draining lymph node groups and sentinel nodes in melanoma and breast cancer

Patient Prep:

- None

Exam Time:

- Breast cancer with no imaging- 10 minutes
- Melanoma- 60-120 minutes

Equipment and Energy:

- Gamma camera: Dual head, large field of view
- Energy: 140 keV with a 20% window

Protocol- breast injection:

- Breast injection using Tc-99m tilmanocept is injected by the nuclear medicine technologist or approved surgeon with a single intradermal injection in the upper outer quadrant, adjacent to the nipple, at the circumareolar margin
- *NOTE: It is imperative to inject 50 mcg mass of the drug (tilmanocept). The pharmacy will provide 50 mcg total, regardless of mCi amount. If the dose is a little high in mCi, you will need to have the radiologist sign off because though it is high in mCi it contains the 50 mcg of tilmanocept required. Therefore, do not remove any volume to reduce the mCi because this would not deliver the required mass of tilmanocept.*
- No imaging is performed in Nuclear Medicine

Protocol- melanoma:

- Melanoma injections are performed by the nuclear medicine technologist around the melanoma site. There are two options for administration, either two or four intradermal injections. For two injections, they are to be spaced evenly at either 3 and 9 o'clock or 12 and 6 o'clock positions. For four injections, they are to be spaced evenly at 12, 3, 6, and 9 o'clock positions surrounding the lesion.
- *NOTE: It is imperative to inject 50 mcg mass of the drug (tilmanocept). The pharmacy will provide 50 mcg total whether we order two or four injections, regardless of mCi amount. Therefore, it is necessary to inject the total amount in the syringes that we receive from the pharmacy. If the dose is a little high in mCi, you will need to have the radiologist sign off because though it is high in mCi, it contains the 50 mcg of tilmanocept required. Therefore, do not remove any volume to reduce the mCi because this would not deliver the required mass of tilmanocept.*
- Images should begin immediately after injection.
- Images should be done every 5 minutes.
 - Back- axilla, groin, and neck
 - Legs- pelvis and posterior knees

- Arms- axilla, neck, elbow
- Throughout the imaging, take transmission films with the cobalt sheet source to outline the body.
- Mark the patient's skin where the sentinel lymph node is on film with surgical marker at the end of the exam

Processing:

- Snapshot images and send to PACS for review

MUGA

Isotope:

Tc99m RBC's

Adult Dose:

30 mCi Tc99mUlratag RBC

Order 40mCi Tc99mO4- to use for tagging the red blood cells.

Indications:

- CAD, CHF, chemo.

Patient Prep:

- None

Exam Time:

- Initially 45 mins

Equipment and Energy:

- Gamma camera: Dual head, Large field of view
- Energy: 140 keV with a 20% window

Protocol:

- Draw 3mL of blood from patient and tag using the Ultra tag kit
- When the blood is ready position the patient on the table.
- EKG electrodes are placed. Make sure the R wave produces a positive and clear voltage spike to the computer.
- Reinject the patient.
- Take LAO image at 45 degrees
- Take Anterior image

Processing:

- Process the images with the computer program to calculate the EF for the left ventricle using the LAO image.