

PYLORIC ULTRASOUND

Patient Sticker

Date _____ Ordering _____ Tech _____

History: Patient age: _____ Gender: M / F First born? Y / N

Indication Projectile Vomiting Weight Loss Inability to Gain or Maintain Weight
 Palpable Midline Mass Other _____

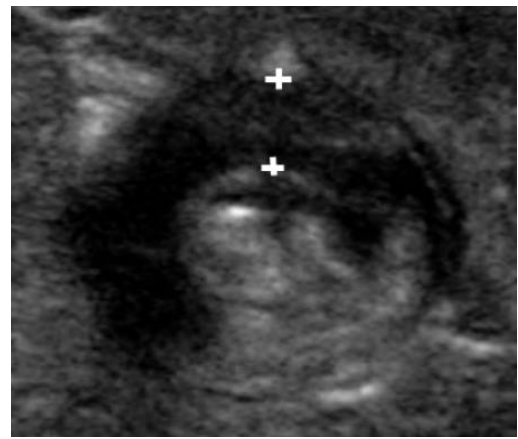
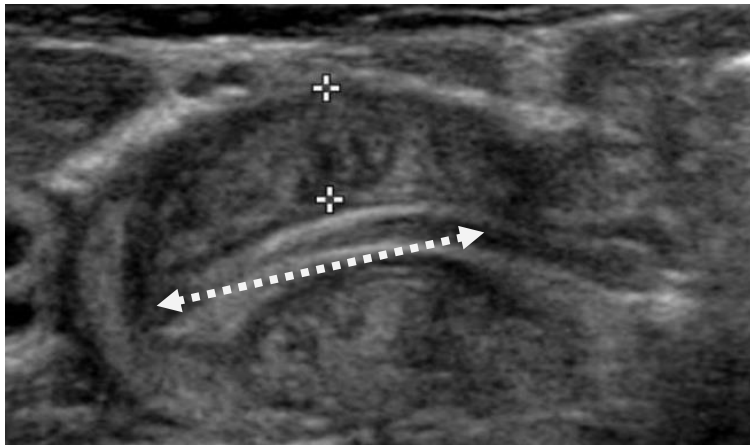
Ultrasound Findings: _____

Single wall muscle thickness: _____ mm

Channel Length _____ mm

Pyloric Channel Open? : Y N

Comments: _____



Normal Findings	
Single wall muscle thickness:	< 3 mm
Channel length	< 16 mm