

CT Protocols

○ Index	1 - 2
○ Notes	3 - 4
• Neuro	
○ Stereotactic Brain, Tumor Localization	5
○ Code Stroke (Head)	6
○ Adult Brain with and without contrast (Routine)	7
○ Pediatric Brain	8
○ Posterior Fossa	9
○ Temporal Bone or IAC	10
○ Sinuses (Axial & Coronal)	11
○ Sinuses (Stryker Protocol)	12
○ Orbits (Axial / Facial)	13
○ Sella (Axial / Coronal)	14
○ Cribriform Plate / CSF Leak (Axial / Coronal)	15
○ Base of Brain / Neural Foraminal / Cranial Nerve	16
○ Larynx	17
○ Neck of Hyperparathyroidism	18
○ Neck & Mediastinum	19
○ Spine (Trauma)	20
○ Spine (Non-Trauma)	21
○ Perfusion Head with and without contrast	22
○ CTA Head with contrast	23
○ CTA Carotids	24
○ CTV Brain	25
○ Stealth Brain	26
• Abdomen & Pelvis	
○ Adrenal Washout	27
○ CT Urogram:	28 - 29
○ CT & CTA Chest, Abdomen & Pelvis with contrast (Trauma)	30

○	CT Abdomen & Pelvis (Acute GI Bleed)	31
○	Cystogram	32
○	Enteroclysis	33
○	Enterography	34
○	Liver (Multi Phase) *Known or suspected tumors, see Notes	35
○	Pancreas	36
○	Radiation Oncology Therapy Planning Protocol	37
○	Renal Mass	38
○	Abdomen & Pelvis (Routine)	39
○	CT Colonography	40
○	CT Venogram Abdomen/Pelvis	41
○	CTA Abdomen & Pelvis with Run-off	42
●	Chest	
○	Chest/Abdomen/Pelvis – with only (Routine)	43
○	Chest with or without contrast (Routine)	44
○	High Resolution Chest	45
○	Chest Angio Protocol (PE)	46
○	Coronary Artery Calcium Score	47
○	Cardiac (Heart) Score (coronary artery or pulmonary vein)	48
	Overread (Addendum)	
○	Aortic Dissection – Chest w/o & CTA Chest/Abd/Pelvis with	49
○	Esophogram	50
○	Low Dose Lung Screening & Follow-up Lung screening	51
●	Extremity	
○	Shoulder	52
○	Long Bone (Humerus, Radius/Ulna, Femur, Tibia/Fibula)	53
○	Elbow	54
○	Wrist	55
○	Hand/Fingers	56
○	Pelvis/Hip	57
○	Knee	58
○	Ankle	59
○	Foot/Toes	60

- **Notes:**

- **Creatinine needed if:**

- Diabetic, HBP requiring medication, on Metformin, over 60 years of age, kidney/renal problems (such as transplant, single kidney, kidney Ca, kidney surgery, decreased kidney function, or see a kidney/renal doctor).

- **IV CONTRAST:**

Multiphase CT is indicated for the following known or suspected tumors: (Typical contrast 35 s, 75 s, 4 min (*timing is based on those scanners without bolus tracking*))

- Neuroendocrine tumors (Includes: carcinoid tumor, pancreatic neuroendocrine tumors, pheochromocytoma, and other neuroendocrine tumors. Excludes: small and large cell lung cancers (also referred to as neuroendocrine lung tumors))
- GIST (gastrointestinal stromal tumors from any site)
- Thyroid cancer (any type)
- Adrenal malignancy (known primary adrenal carcinoma)
- Liver (hepatocellular carcinoma, including screening for hepatocellular carcinoma, and cholangiocarcinoma)
- ❖ If order includes Chest (i.e. Chest/Abdomen/Pelvis) scan times can be 25 sec / 75 sec / and 5-minute delay, however if scanner can accommodate, the preference is 35 sec. / 75 sec / and 5-minute delay.
- ❖ If there is a question of whether or not the patient's malignancy or suspected malignancy is included above, please contact a body radiologist for clarification.

- **A unique type of Multiphase CT study is done for:**

- Liver (after IR treated) for follow up of IR treated liver tumors use Quad phase and add w/o study followed by 35s, 75 s, 4 min) because there may be high attenuation material that might mimic enhancing tumor otherwise.
- Pancreas (40 s, 80 s), use water for oral contrast 32 oz. within 20 min of scan (scans are in the late arterial phase and in Portal venous phase)
- Adrenal mass work up (w/o, scan at 70 s, scan at 15 min)
- CT Urograms (looking for renal / urothelial masses)
- ❖ For other tumor types that are not listed above then routine CT Abdomen protocol is to be followed (that is portal venous phase images only unless otherwise requested by ordering clinician or radiologists).

○ **ORAL CONTRAST:**

(1) **Positive oral contrast (shown as white on CT imaging, using water soluble, not barium contrast)** is to be used in abdominal and pelvic CTs done for the following indications, unless specifically requested to be done without oral contrast by the ordering clinician or radiologist:

- Abscess
- Fistula
- Bowel leak
- Optional (i.e., if specified by ordering clinician or radiologist): Bowel obstruction (give only amount tolerated by patient)

or

(2) If specified by the ordering clinician.

- If a study is ordered without oral contrast, then do as ordered (without oral contrast as ordered there is no need to call radiologist for most cases).
- If a question is asked (prior to placing the order) by clinical team members there might be some benefit (to assess for tumor involving, or near bowel) of using positive oral contrast for the following tumor types:
 - Ovarian
 - GIST (gastrointestinal stromal tumor)
 - Extrahepatic Bile duct (cholangiocarcinoma of the extrahepatic bile ducts)
 - Breast (if already known to be metastatic) and
 - Lung (if already known to be metastatic)
 - and occasionally other types of tumors not listed

In summary, if oral contrast is requested, use **positive oral contrast** for all tumor types, except pancreatic masses (see below).

For the following types of neoplasm use **negative contrast (low density on CT such as water or Breeza)**.

- Pancreas mass (for initial staging use water, 32 oz. (about 950 mL) , drink entire amount (or as much as tolerated) within 20 to 30 minutes of scan)
- CT Enterography (No food for at least 4 hours prior to scan, drink three (3) bottles of Breeza (each bottle = 500 mL), or about 1 bottle per 20 minutes prior to scan or as much as tolerated) or alternatively use VoLumen (each bottle = 450 mL) drinking 3 bottles over about 1 hour prior to scan. For smaller patients over the one hour use 20 mL/kg of Breeza or Volumen over one hour prior to scan)

(STEREOTACTIC) STEALTH BRAIN TUMOR LOCALIZATION

REGION OF INTEREST: BRAIN TUMOR; LOCATIONS OF FIDUCIALS/ CRANIAL APPARATUS
ORAL CONTRAST: NONE
SCOUT FILM: LATERAL
PHASE OF RESPIRATION: PATIENT USUALLY SEDATED WITH ANESTHESIA
SLICE THICKNESS: 2 mm
ANATOMICAL COVERAGE: Base of the skull through Vertex – NEUROSURGEON TO DIRECT AREA OF SCAN.
INTRAVENOUS CONTRAST: Non-Ionic 100ml maximum when ordered

COMMENTS:

1. PATIENT IS USUALLY UNDER HEAVY SEDATION OR GENERAL ANESTHESIA. PATIENT IS SCANNED TABLE TOP, OR LOCKING DEVICE FOR HALO, AND SUPINE. HEAD CAN BE ON A SHEET OR TOWEL, LEVEL AND STRAIGHT IF NO HALO.
2. PATIENT MAY HAVE A DEVICE (HALO) BOLTED TO HIS HEAD BY THE NEUROSURGEON AND ASSISTS IN POSITIONING PRIOR TO SCAN.

INDICATION: BRAIN TUMOR

	Ax	Ax
Slice	2 x 2	2 x 2
Scan	W/O	WITH
Series Description	AX	AX +C

CODE STROKE ADULT BRAIN WITHOUT

REGION OF INTEREST: BRAIN; Base of Skull to Vertex of Skull
FOV: 250mm (adjust to skull size)
SCOUT FILM: LATERAL
SLICE THICKNESS: 4 mm x 4 mm
ALGORITHM: STD/Body
INTRAVENOUS CONTRAST: None
COMMENTS: Call Radiologist for reading while on the phone, call ED for RAV of reading and put into EPIC.
RECONSTRUCTIONS: Axial, Sagittal, & Coronal - 4 x 4 mm
Axial Bone - 2 x 2 mm

INDICATION: STROKE or STROKE symptoms within CODE STROKE time limits

** CODE STROKE IS TO BE DONE AS IMMEDIATELY AS POSSIBLE. CALL RADIOLOGIST AFTER

	Ax	Ax (Bone)	Sag	Cor
Slice	4 x 4	2 x 2	4 X 4	4 x 4
Scan	W/O	W/O	W/O	W/O
Series Description	AX	AX BONE	SAG	COR

ROUTINE ADULT BRAIN with & without contrast

REGION OF INTEREST: BRAIN; Base of Skull to Vertex of Skull
FOV: 250 mm (adjust to skull size)
SCOUT FILM: LATERAL
SLICE THICKNESS: 4 mm
SLICE INTERVAL: 4 mm
ALGORITHM: MED
INTRAVENOUS CONTRAST 1ml/pound up to max 100ml non-Ionic contrast
Delay should be approx. 45 - 60 sec.

COMMENTS:

- Reconstruct algorithm.
 - Axial Bone
 - Axial, Sagittal & Coronal Soft Tissue
- A longer delay can be used on IVC if only looking for METS
- Techs need to detail site of trauma when typing in history
- Angle gantry to petrous ridge on all scans when possible.

INDICATION: HEADACHES, DIZZINESS, HEAD TRAUMA, METASTATIC CANCER

	Ax (Bone)	Ax (Soft)	Sag (Soft)	Cor (Soft)	Ax (Bone)	Ax (Soft)	Sag (Soft)	Cor (Soft)
Slice	2 x 2	4 x 4	4 X 4	4 x 4	2 x 2	4 x 4	4 X 4	4 x 4
Scan	W/O	W/O	W/O	W/O	WITH	WITH	WITH	WITH
Series Description	AX BONE	AX SOFT	SAG SOFT	COR SOFT	AX BONE +C	AX SOFT +C	SAG SOFT +C	COR SOFT +C

PEDIATRIC BRAIN

REGION OF INTEREST: PEDIATRIC BRAIN
SCOUT FILM: LATERAL
SLICE THICKNESS: 3mm x 3mm
ANATOMICAL COVERAGE: BASE OF the SKULL through VERTEX
PITCH: No Greater than 2 if done Helical.
INTRAVENOUS CONTRAST: 2ml/kg body weight, maximum 75ml when ordered.

COMMENTS:

1. Reconstruct algorithm.
 - Axial Bone
 - Axial, Sagittal & Coronal Soft Tissue
2. FOV should include entire head and soft tissue with visualization of the entire bony cranium.
3. X-Care, Care dose and IR reconstruction always used for optimal dose reduction
4. Check for motion.
5. Angle approximately 25 degrees caudad to Reid's base line, (if using sequential mode) thus superimposing the supraorbital ridge to avoid lens exposure if possible. (you Cannot Angle with some Helical scanners)
6. 3D images can be reconstructed if required for diagnosis.

INDICATION: HEADACHE, SEIZURES, SUSPECTED MASS, TRAUMA, BIRTHING COMPLICATIONS

	Ax (Bone)	Ax (Soft)	Sag (Soft)	Cor (Soft)	Ax (Bone)	Ax (Soft)	Sag (Soft)	Cor (Soft)
Slice	3 x 3	3 x 3	3 X 3	3 x 3	3 x 3	3 x 3	3 X 3	3 x 3
Scan	W/O	W/O	W/O	W/O	WITH	WITH	WITH	WITH
Series Description	AX BONE	AX SOFT	SAG SOFT	COR SOFT	AX BONE +C	AX SOFT +C	SAG SOFT +C	COR SOFT +C

POSTERIOR FOSSA

REGION OF INTEREST: POSTERIOR FOSSA (always do head study with this protocol)

SCOUT FILM: LATERAL

SLICE THICKNESS: 2 mm

SLICE INTERVAL: 2 mm

INFERIOR EXTENT: FORAMEN MAGNUM

SUPERIOR EXTENT: THIRD VENTRICLE

INTRAVENOUS CONTRAST: Non-Ionic 75ml - 135ml maximum

COMMENTS: Do entire brain in conjunction with Posterior Fossa study at 4 mm

INDICATION: HEADACHES

	Ax (Bone)	Sag (Bone)	Cor (Bone)	Sag (Soft)	Cor (Soft)
Slice	2 x 2	2 X 2	2 x 2	2 X 2	2 x 2
Scan	W/O	W/O	W/O	W/O	W/O
Series Description	AX BONE	SAG BONE	COR BONE	SAG SOFT	COR SOFT

TEMPORAL BONE or IAC

REGION OF INTEREST: TEMPORAL BONE or IAC
SCOUT FILM: LATERAL
SLICE OF THICKNESS: 0.5 mm
SLICE INTERVAL: 0.5 mm (Axial MPR both sides)
INFERIOR EXTENT: BASE OF PETROUS BONE OR TIP OF MASTOID
SUPERIOR EXTENT: THROUGH MASTOIDS
INTRAVENOUS CONTRAST: If contrast ordered, Non-Ionic 135ml maximum

COMMENTS:

1. Scan Axial with coronal reformats. No direct coronal
2. Cover entire mastoids
3. Reconstruction – Bone and Soft algorithm
4. Axial & Coronal whole head
5. Axial & Coronal limited FOV to left and right separately
6. FOR HISTORY OF ACOUSTIC NEUROMA, MRI PREFERRED OVER CT,
IF NOT A CONTRAINDICATION

INDICATION: Cholesteatoma, Trauma, Surgery, Chronic Otitis Media, Loss of Hearing, Acoustic Neuroma

	Ax (Bone) Whole Head	Cor (Bone) Whole Head	AX (Bone) Left & Right	Cor (Bone) Left & Right	AX (Soft)	Cor (Soft)
Slice	1 x 1	1 X 1	.5 x .5	.5 x .5	1 x 1	1 x 1
Scan	W/O	W/O	W/O	W/O	WITH	WITH
Series Description	AX BONE	COR BONE	SAG BONE	COR BONE	AX SOFT	Cor SOFT

SINUSES

REGION OF INTEREST: AXIAL SINUSES
SCOUT FILM: LATERAL
SLICE THICKNESS: 3 mm
SLICE INTERVAL: 3 mm (Never direct Coronal. Always helical scan with Coronal reformats)
INFERIOR EXTENT: BASE OF MAXILLARY SINUSES
SUPERIOR EXTENT: ABOVE TOP OF FRONTAL SINUSES
INTRAVENOUS CONTRAST: NON-IONIC 75ml or 100 ml maximum if ordered

COMMENTS:

1. FOV 20, standard & bone algorithm.
2. Images should include entire orbits and anterior clinoids and as much mastoids as possible
3. Reconstruction
 - Axial, Sagittal, Coronal Bone
 - Axial soft tissue

INDICATION: SINUSITIS

	Ax (Bone)	Sag (Bone)	Cor (Bone)	Ax (Soft)
Slice	1 x 1	1 X 1	1 x 1	1 x 1
Scan	W/O	W/O	W/O	W/O
Series Description	AX BONE	SAG BONE	COR BONE	AX SOFT

STRYKER SINUS PROTOCOL

REGION OF INTEREST: ENTIRE SINUSES, through head.
SCOUT: LATERAL
SCAN PARAMETERS 120KV / 150 mAs (No care dose) .5 SEC. ROTATION, BONE / SHARP ALGORITHM.
SLICE THICKNESS: 1 mm
SLICE INTERVAL: 1 mm
POSTERIOR EXTENT: BASE OF MAXILLA, INCLUDE SOFT PALATE (scan inferior to superior)
SUPERIOR EXTENT: TOP OF HEAD (MUST SEE AIR)

COMMENTS:

1. Patient scanned axial, 250mm FOV, with coronal reformats, 1 mm x 1mm, use 19cm/190mm FOV and send all images to PACS.
2. Scan patient TABLETOP, (Sponge), not in head holder. Axial views. No angle.
3. Get patients upper teeth perpendicular as possible to table. If you must build up patient's head to get their teeth perpendicular to table, use towels or washcloths. Do not cut any of the anterior anatomy.

INDICATION: SINUSITIS

	Ax (Bone)	Sag (Bone)	Cor (Bone)	Ax (Soft)
Slice	1 x 1	1 X 1	1 x 1	1 x 1
Scan	WITHOUT	WITHOUT	WITHOUT	WITHOUT
Series Description	AX BONE	SAG BONE	COR BONE	AX SOFT

FACIAL BONES, ORBITS, OPTIC NERVE, SINUSITIS, (MASS, CELLULITIS,)

REGION OF INTEREST: ORBITS FOR TUMOR, MASS, OPTIC NERVE, AXIALS, FACIAL OR ORBITAL CELLULITIS
SCOUT FILM: LATERAL
SLICE THICKNESS: 2 mm
SLICE INTERVAL: 2 mm
RECONSTRUCTION: Axial, Sagittal & Coronal - bone & soft tissue – 2 x 2 mm
INFERIOR EXTENT: BENEATH INFRAORBITAL RIDGE/BELOW MANDIBLE FOR FACIAL BONES
SUPERIOR EXTENT: ABOVE FLOOR OF FRONTAL SINUS
INTRAVENOUS CONTRAST: NON-IONIC 75 ml or max of 100 ml if ordered

COMMENTS: Images should include entire orbits and anterior clinoid.

INDICATION: SINUSITIS, FACIAL/ORBITAL CELLULITIS, MASS OR TUMOR

	Ax (Bone)	Sag (Bone)	Cor (Bone)	Ax (Soft)	Sag (Soft)	Cor (Soft)
Slice	2 x 2	2 X 2	2 x 2	2 x 2	2 x 2	2 x 2
Scan	W/O	W/O	W/O	W/O	W/O	W/O
Series Description	AX BONE	SAG BONE	COR BONE	AX SOFT	SAG SOFT	COR SOFT

SELLA

REGION OF INTEREST: AXIAL SELLA
SCOUT FILM: LATERAL & AP
SLICE THICKNESS: 1 mm
SLICE INTERVAL 1 mm
POSTERIOR EXTENT: START BELOW SELLA
ANTERIOR EXTENT 2 - 3 cm ABOVE SELLA
INTRAVENOUS CONTRAST: NON-IONIC 100ml maximum

COMMENTS:

1. USE 140 KV 300+ MA
2. Sagittal & Coronal bone & soft tissue algorithm

INDICATION: PITUITARY TUMOR

	Ax	Ax	Sag (Bone)	Cor (Bone)	Sag (Soft)	Cor (Soft)
Slice	1 x 1	1 x 1	1 X 1	1 x 1	1 x 1	1 x 1
Scan	W/O	WITH	W/O	W/O	W/O	W/O
Series Description	AX	AX +C	SAG BONE	COR BONE	SAG SOFT	COR SOFT

CORONAL/AXIAL IMAGES OF THE CRIBRIFORM PLATE OR FACIALS FOR CSF LEAK

REGION OF INTEREST: THE CRIBRIFORM PLATE FOR CSF LEAK - Axial and Coronal if patient can tolerate position
SCOUT FILM: LATERAL
SLICE THICKNESS: 1 mm
SLICE INTERVAL: 1 mm
ANTERIOR EXTENT: THROUGH FRONTAL SINUS (NASION)
POSTERIOR EXTENT: ANTERIOR CLINOIDS

COMMENTS:

1. FOV 14, SOFT TISSUE AND BONE ALGORITHMS
2. CORONAL SHOULD BE PERPENDICULAR TO THE CRIBRIFORM PLATE, IF POSSIBLE.
3. AXIALS THROUGH THE FRONTAL SINUSES ARE DONE. BEGIN AT THE NASION AND CONTINUE UNTIL OUT OF THE SINUS.

INDICATION: CSF LEAK

	Ax (Bone)	Cor (Bone)	AX (Soft)	Cor (Soft)
Slice	1 X 1	1 x 1	1 x 1	1 x 1
Scan	W/O	W/O	W/O	W/O
Series Description	AX BONE	COR BONE	AX SOFT	COR SOFT

BASE OF BRAIN FOR NEURAL FORAMINA AND CRANIAL NERVE DISORDERS

REGION OF INTEREST: BASE OF BRAIN FOR NEURAL FORAMINA AND CRANIAL NERVE DISORDERS
SCOUT FILM: LATERAL
SLICE THICKNESS: 1 mm
SLICE INTERVAL: 1 mm
INFERIOR EXTENT: BOTTOM OF FORAMEN MAGNUM
SUPERIOR EXTENT: THIRD VENTRICLE
INTRAVENOUS CONTRAST: NON-IONIC 100ml

COMMENTS:

1. HARD PALATE PERPENDICULAR WITH BASE OF SKULL (CHIN-UP) FOV 25, SOFT TISSUE AND BONE ALGORITHMS.
2. PATIENTS WITH FACIAL NERVE DISORDERS ALSO REQUIRE THESE VIEWS. EVEN IF ROUTINE HEAD ORDERED.
3. GIVE VERY SPECIFIC HX

INDICATION: FACIAL NUMBNESS, PAIN, TASTE ALTERATIONS, AND BELL'S Palsy

	Ax (Bone)	Cor (Bone)	Ax (Soft)	Cor (Soft)
Slice	1 X 1	1 x 1	1 x 1	1 x 1
Scan	WITH	WITH	WITH	WITH
Series Description	AX BONE +C	COR BONE +C	AX SOFT +C	COR SOFT +C

LARYNX

REGION OF INTEREST: LARYNX
SCOUT FILM: LATERAL
SLICE THICKNESS: 1 mm (3mm for Neck)
SLICE INTERVAL: 1 mm (Coronal & Sagittal thru Larynx) 3mm thru neck
SUPERIOR EXTENT: Orbits
INFERIOR EXTENT: AP window
INTRAVENOUS CONTRAST: Non-Ionic 135ml maximum

COMMENTS:

1. THE NECK SHOULD BE HYPEREXTENDED.
2. THE PATIENT SHOULD BE INSTRUCTED NOT TO SWALLOW DURING IMAGING.
3. A SMALL FOV (200mm) FOR LARYNX ONLY
4. REMOVE DENTAL WORK IF POSSIBLE.
5. THIS STUDY DONE IN CONJUNCTION WITH A NECK STUDY
6. PHONATION (“E”) CAN BE USED FOR DISTENDING THE PYRIFORM SINUSES, SUPRAGLOTTIC TUMOR AROUND THE SINUSES, AND EPIGLOTTIC FOLDS

INDICATION: PARALYZED VOCAL CORD, HOARSENESS

	Ax (Bone)	Sag (Bone)	Cor (Bone)	AX (Soft)	Sag (Soft)	Cor (Soft)
Slice	1 X 1	1 x 1	1 x 1	1 x 1	1 x 1	1 x 1
Scan	W/O	W/O	W/O	W/O	W/O	W/O
Series Description	AX BONE	SAG BONE	COR BONE	AX SOFT	SAG SOFT	COR SOFT

NECK FOR PRIMARY HYPERPARATHYROIDISM

REGION OF INTEREST: NECK AND MEDIASTINUM
SCOUT: LATERAL OR A/P. BOTH IF NEEDED
PHASE OF RESPIRATION: “STOP BREATHING, DON’T BREATHE OR SWALLOW “
SLICE THICKNESS: 3 mm
SLICE INTERVAL 3 mm (Coronal/Sagittal MPR)
SUPERIOR EXTENT: Mid Orbits
INFERIOR EXTENT: Carina
INTRAVENOUS CONTRAST: NON-IONIC – 75 ml or 135 ml maximum if ordered

Scan 1: W/O contrast
Scan 2: 25 sec Delay
Scan 3: 80 sec Delay

Comments: SAGITTAL AND CORONAL REFORMATS REQUIRED.

INDICATION: Parathyroid Adenoma, Ectopic parathyroid gland, Hyperparathyroidism.

	Ax	Ax	Sag (Bone)	Cor (Bone)	Sag (Soft)	Cor (Soft)
Slice	3 x 3	3 x 3	2 x 2	2 x 2	2 x 2	2 x 2
Scan	W/O	WITH	W/O	W/O	W/O	W/O
Series Description	AX	AX +C	SAG BONE	COR BONE	SAG SOFT	COR SOFT

NECK AND MEDIASTINUM

REGION OF INTEREST: NECK AND MEDIASTINUM
 SCOUT: LATERAL AND A/P IF NEEDED
 PHASE OF RESPIRATION: “STOP BREATHING, DON’T BREATHE OR SWALLOW “
 SLICE THICKNESS: 3 mm
 SLICE INTERVAL 3 mm (Coronal/Sagittal MPR)
 SUPERIOR EXTENT: Mid Orbits
 INFERIOR EXTENT: AP Window
 INTRAVENOUS CONTRAST: NON-IONIC – 75 ml or 135 ml maximum

- IF STONE SUSPECTED DO W/WO STUDY
- ALL SWELLING, MASS OR OTHER PALPABLE AREAS NEED MARKED OR DOCUMENTED NOT ABLE TO PALPATE.
- NECK SOFT TISSUE SHOULD ALWAYS BE DONE WITH IV CONTRAST TO DIFFERENTIATE BETWEEN LYMPH NODES AND VESSELS.
- 45 SECOND DELAY
- FOR VOCAL CORD PARALYSIS; INFERIOR ASPECT OF SCAN; AP WINDOW/BRONCHI (see Larynx protocol)

INDICATION: NECK PAIN/SWELLING, DIFFICULTY SWALLOWING, NECK MASS, SALIVARY STONE

	Ax	Ax	Sag (Bone)	Cor (Bone)	Sag (Soft)	Cor (Soft)
Slice	3 x 3	3 x 3	3 x 3	3 x 3	3 x 3	3 x 3
Scan	W/O	WITH	W/O	W/O	W/O	W/O
Series Description	AX	AX +C	SAG BONE	COR BONE	SAG SOFT	COR SOFT

TRAUMA SPINE

REGION OF INTEREST: CERVICAL, THORACIC, AND LUMBAR
CONTRAST: No oral or IV
INSPIRATION: QUIET BREATHING
SLICE THICKNESS: 2 mm
SLICE INTERVAL: 2 mm
SUPERIOR EXTENT: APPROX, 1 ½ - 2-disc spaces ABOVE AREA OF CONCERN
INFERIOR EXTENT: APPROX. 1 ½ - 2-disc spaces BELOW AREA OF CONCERN
* Usually entire spine

- SCAN CONTINUOUS THROUGH AREA OF INTEREST.
- Reconstruction:
 - Axial – Bone & Soft tissue
 - Coronal – Bone
 - Sagittal – Bone & Soft tissue
- MPR'S ARE DONE IN BONE
- Off Axial Reformat (follow the spine, not the table)
- 3D IMAGES ARE TO BE DONE IF ORDERED ON SCRIPT OR AT RADIOLOGISTS REQUEST

INDICATION: TRAUMA, PAIN, FRACTURE

	Ax (Bone)	Sag (Bone)	Cor (Bone)	Ax (Soft)	Sag (Soft)
Slice	2 x 2	2 x 2	2 x 2	2 x 2	2 x 2
Scan	W/O	W/O	W/O	W/O	W/O
Series Description	AX BONE	SAG BONE	COR BONE	AX SOFT	SAG SOFT

SPINE NON-TRAUMA (CERVICAL, THORACIC, AND LUMBAR)

REGION OF INTEREST: SPINE, CERVICAL, THORACIC, LUMBAR
CONTRAST: No oral or IV
SCOUTS: LATERAL & AP IF NEEDED
SLICE THICKNESS: 2 mm
SLICE INTERVAL: 2 mm
SUPERIOR EXTENT: APPROX, 1 ½ - 2-disc spaces ABOVE AREA OF CONCERN
INFERIOR EXTENT: APPROX. 1 ½ - 2-disc spaces BELOW AREA OF CONCERN

- USE PILLOW OR PAD UNDER KNEE FOR LUMBAR TO DECREASE ANGULATION OF L5-S1.
- ADULT OR CHILD WITH HISTORY OF SPONDYLOLYSIS DO L3-S1
- DISCOGRAM STUDIES START JUST ABOVE CONTRAST IN DISC AND END JUST BELOW CONTRAST.
- Off Axial Reformat (follow the spine, not the table)
- 3D IMAGES TO BE DONE ON SPINES IF ORDERED ON SCRIPT OR REQUESTED BY RADIOLOGISTS.
- Reconstruction: Axial, Sagittal, & Coronal – Soft Tissue and Bone

INDICATION: BACK PAIN, SPONDYLOSIS, SPINAL STENOSIS

	Ax (Bone)	Sag (Bone)	Cor (Bone)	Ax (Soft)	Sag (Soft)	Cor (Soft)
Slice	2 x 2	2 x 2	2 x 2	2 x 2	2 x 2	2 x 2
Scan	W/O	W/O	W/O	W/O	W/O	W/O
Series Description	AX BONE	SAG BONE	COR BONE	AX SOFT	SAG SOFT	COR SOFT

HEAD CT With & Without PERFUSION

REGION OF INTEREST: BRAIN AND VESSELS IF ORDERED
IV CONTRAST: ISOVUE 370 VISIPAQUE 320 OMNI 350
SLICE THICKNESS: 5 MM CONES 8i CINE 1 SECOND SCAN X 45-50 SECONDS
FOR PERFUSION IMAGES 700 + IMAGES

PROCEDURE: Scan must be completed and dictated within 45 minutes of order. (1) Routine head without IV contrast for most code stroke orders. If MD wants WITH AND WITHOUT study Perfusion and Angio

1. Routine head without (2) Angio head using no more than 100 ml of contrast. (3) Perfusion head study using 50 ml of contrast. (4) Reprocess head from Angio to regular head or brain cuts (5MM).
2. Send Angio Head images and 700 + perfusion head images to workstation. Work up angio brain and then work up perfusion images.
3. Send Head without, Reprocessed head with, and finished perfusion 4-5 images to PACS don't send all of perfusion raw images to PACS.
4. Contrast is injected at 4-5ml second (follow angio protocol rates for perfusion study) use 150 ml of contrast 100ml on angio then use 50ml on Perfusion study.
5. Work up Procedure for Perfusion
6. Click Perfusion images
7. Pick Perfusion 3
8. 3 Click on CT Perfusion (2nd) box
9. Apply Registration
10. Next
11. Adjust thresholds air and bone
12. Next
13. Create ellipse ROI adjust to size and put over artery Next
14. Same as above on vein put 2 additional ROI in brain tissue Next Adjust post enhancement images move back one number Next
15. Compute, close and save images 4 in all send to PACS

CTA HEAD WITH (Angiography 3D)

REGION OF INTEREST: CIRCLE OF WILLIS
INTRAVENOUS CONTRAST: 135 ml max of ISOVUE 370
SCOUT: AP & LATERAL if needed.
RESPIRATION: QUIET BREATHING IN HEAD HOLDER
SLICE THICKNESS: 1 x 1 mm
RECONSTRUCTION: 1 x 1 mm
SUPERIOR EXTENT: TOP OF HEAD
INFERIOR EXTENT: BASE OF SKULL.

- Bolus tracking region of interest in Aortic arch
- Reconstruction:
 - Axial, Sagittal, and Coronal 1 mm with separate FOV limited to head and neck
 - Axial, Sagittal, and Coronal MIP for head
- CT Head does not need repeated. CT Head without (3 x 3) only needed if non-contrasted head has not been complete previously.

INDICATION: KNOWN ANEURYSM, STROKE, CIRCULATORY DISEASE

	Ax	Ax	Sag	Cor	Ax MIP Head	Sag MIP Head	Cor MIP Head
Slice	1 x 1	1 x 1	1 x 1	1 x 1	5 x 3	5 x 3	5 x 3
Scan	W/O	WITH	WITH	WITH	WITH	WITH	WITH
Series Description	AX	AX +C	SAG +C	COR +C	AX MIP HEAD +C	SAG MIP HEAD +C	COR MIP HEAD +C

CT ANGIOGRAPHY (CTA) OF THE CAROTIDS

REGION OF INTEREST: CAROTIDS
 ORAL CONTRAST: NONE
 INTRAVENOUS CONTRAST: Non-Ionic 135 ml maximum
 The bolus tracking region of interest in the Aortic arch.
 SCOUT FILM: AP & LATERAL IF NEEDED
 PHASE OF RESPIRATION: Stop breathing
 SLICE THICKNESS: 1 mm
 RECONSTRUCTION: 1 mm for Axial, Sagittal, & Coronal
 Sagittal & Coronal MIPs
 Sagittal and Coronal Reformats

 SUPERIOR EXTENT: MID-ORBITS
 INFERIOR EXTENT: AORTIC ARCH AT ORIGIN OF GREAT VESSELS.
 POST PROCESSING: SAGITTAL AND CORONAL REFORMATS.

 INDICATION: CAROTID STENOSIS, STROKE

	Ax	Sag	Cor	Sag MIP Neck	Cor MIP Neck	Sag Recon	Cor Recon
Slice	1 x 1	1 x 1	1 x 1			3 x 3	3 x 3
Scan	WITH	WITH	WITH	WITH	WITH	WITH	WITH
Series Description	AX +C	SAG +C	COR +C	SAG MIP NECK +C	COR MIP NECK +C		

CTV HEAD WITH CONTRAST

REGION OF INTEREST; ENTIRE BRAIN, VEINS
ORAL CONTRAST; NONE
SCOUT/TOPOGRAM; LATERAL
INTRAVENOUS CONTRAST; Non-Ionic 100ml maximum
SLICE THICKNESS; 1 mm
SLICE INTERVAL; 1 mm
RECONSTRUCTION; 1 mm for Axial, Sagittal, & Coronal
Sagittal & Coronal MIPs

COMMENTS; MRV OF THE HEAD IS PREFERRED BY RADIOLOGIST

INDICATION; DURAL SINUS THROMBOSIS

	Ax	Ax	Sag	Cor	Ax MIP Head	Sag MIP Head	Cor MIP Head
Slice	1 x 1	1 x 1	1 x 1	1 x 1			
Scan	W/O	WITH	WITH	WITH	WITH	WITH	WITH
Series Description	AX	AX +C	SAG +C	COR +C	AX MIP HEAD +C	SAG MIP HEAD +C	COR MIP HEAD +C

STEALTH BRAIN CT

REGION OF INTEREST:

CONTRAST:

SCOUT IMAGES:

PATIENT POSITION:

SLICE THICKNESS:

SUPERIOR EXTENT:

INFERIOR EXTENT:

ENTIRE HEAD INCLUDING SOFT TISSUE

Non-Ionic

LATERAL

SUPINE, HEAD IS FLAT AND STRAIGHT. NO ANGLED. SPONGE IF SURGICAL HEAD HOLDER USED.

2 X 2 mm with NO ANGLE

ABOVE SKIN AND FIDUCIALS (MARKERS)

BELOW BASE OF SKULL

COMMENTS: 1-3 IS DONE BY SURGERY

1. PT NEEDS 10 FIDUCIAL MARKER IN RANDOM ON HD, 2 WILL BE OVER TUMOR (REFER TO PREVIOUS EXAM)
2. PT NEEDS TO HAVE 10 SMALL AREAS OF HAIR SHAVED THEN CLEAN SKIN WITH ALCOHOL PREP PAD. APPLY FIDUCIALS AND PUT A BLACK DOT IN the CENTER WITH MAGIC MARKER.
3. GIVE PATIENT A SURGERY CAP AND SENT PATIENT EITHER TO SURGERY OR ROOM. FADUCIALS MUST STAY ON PATIENT.
4. SEND AXIAL IMAGES TO THE STEALTH MACHINE.
5. MAKE SURE SURGERY HAS STEALTH TURNED ON PRIOR TO STUDY.
6. DO NOT SHAVE ENTIRE HEAD.

INDICATION: BRAIN TUMOR

	Ax	Ax
Slice	2 x 2	2 x 2
Scan	W/O	WITH
Series Description	AX	AX +C

Adrenal Washout

- Oral Contrast: None
- IV Contrast:
 - Rate: 3cc/sec
 - Hyperlink
- Scan Range: Above dome of liver to iliac crest
- Timing: Without, 75 seconds and 15 min
- Reconstructions:
 - All scans, all phases are to be reconstructed in three planes: axial, coronal, sagittal lined up with the patient (not the table) using a 3 mm slice width (or 3.75 mm if the scanner cannot create 3 mm) and 3 mm slice increment. If the patient is lying oblique (RPO or LPO) on the table, sagittal and coronal images must be aligned with the patient.

		Ax			Cor			Sag	
Slice (mm)	3x3	3x3	3x3	3x3	3x3	3x3	3x3	3x3	3x3
Scan	w/o	75 sec	15 min	w/o	75 sec	15 min	w/o	75 sec	15 min
Series Description	AX	AX+C	AX DEL	COR	COR+C	COR DEL	SAG	SAG+C	AX DEL

CT Urogram (page 1 of 2)

- Ask patients to drink 3 - 12 ounce cups of water beginning 30-60 minutes prior to the exam.
- Ask patients about allergy to Lasix (furosemide) or sulfa drugs. If yes, do not give furosemide.
- Check patient age. Use 2-phase (2 scans) protocol for patients under age 35. Use 3-phase (3 scans) protocol for patients 35 and older.
- Ask patient's body weight.

CT Urogram contrast dose is weight-based:

- Isovue 370 (370 mg iodine/ml): 0.75 ml per pound body weight to maximum of 150 ml.
- Omnipaque 350 (350 mg iodine/ml): 0.8 ml per pound body weight to maximum of 160 ml.
- Isovue or Omnipaque 300 (300 mg iodine/ml): 0.9 ml per pound body weight to maximum of 185 ml

2-phase (split contrast bolus) protocol for patients under 35 years old

1. Scan #1: abdomen & pelvis without. Use kVp 100 or less, if possible (to increase conspicuity of iodine).
2. Administer normal saline 100 ml IV
3. Administer furosemide 10 mg IV (unless allergic)
4. Administer first half of IV contrast media at 3 ml/sec
5. Wait 7 minutes. Towards the end of this time, if the patient is able, please have them roll from side to side to allow for uniform mixing of contrast in the bladder prior to scan #2
6. Administer second half of IV contrast media at 3 ml/sec
7. Scan #2: abdomen & pelvis beginning 90 seconds after start of injection. Use kVp 100 or less, if possible.

3-phase (single contrast bolus) protocol for patients 35+ years old

1. Scan #1: abdomen & pelvis without. Use kVp 100 or less, if possible (to improve conspicuity of iodine)
2. Administer normal saline 100 ml IV
3. Administer furosemide 10 mg IV (unless allergic)
4. Administer contrast media at 3 ml/sec
5. Scan #2: abdomen & pelvis beginning 90 seconds after the start of contrast media injection
6. Wait 7 minutes. Toward the end of this time, if patient is able, please have patient roll from side to side to allow uniform mixing of contrast in the bladder, prior to scan #3 contrast scan.
7. Scan #3: abdomen & pelvis beginning 9 minutes after the start of contrast media injection

Urogram Reconstructions:

- All scans, all phases are to be reconstructed in three planes: axial, coronal, sagittal lined up with the patient (not the table) using a 3 mm slice width (or 3.75 mm if the scanner cannot create 3 mm) and 3 mm slice increment. If the patient is lying oblique (RPO or LPO) on the table, sagittal and coronal images must be aligned with the patient.

	Ax	Ax	Cor	Cor	Sag	Sag
Slice	3x3	3x3	3x3	3x3	3x3	3x3
Scan	W/O	With	W/O	With	W/O	With
Series Description	AX	AX +C	COR	COR +C	SAG	SAG +C

CTA & CT Chest, Abdomen and Pelvis with Contrast (Trauma)

- CTA Chest, Abdomen, Pelvis
 - Scanned at 25 – 35 seconds in 2 – 3 mm slices
- CT Abdomen and Pelvis scanned in portal venous phase
 - Scanned at 70 – 75 seconds in 3 mm slices
- If concern for urinary tract, bladder injury, or hematuria, add 8 – 10 minute delayed phase of Abdomen and Pelvis
- Contrast rate: 3 ml/sec
- Reconstructions:
 - All scans, all phases are to be reconstructed in three planes: axial, coronal, sagittal lined up with the patient (not the table) using a 3 mm slice width (or 3.75 mm if the scanner cannot create 3 mm) and 3 mm slice increment. If the patient is lying oblique (RPO or LPO) on the table, sagittal and coronal images must be aligned with the patient.

	Ax	Ax	Cor	Cor	Sag	Sag
Slice	3x3	3x3	3x3	3x3	3x3	3x3
Scan	75 sec	Delay	75 sec	Delay	75 sec	Delay
Series Description	AX +C	DEL	COR	COR DEL	SAG	SAG DEL

CT Abdomen and Pelvis without and with (Acute GI Bleeding)

- Scan abdomen and pelvis without IV contrast media first
- **Do not give oral contrast**
- IV contrast rate: 4ml/sec
- Scan abdomen and pelvis at 35 seconds
- Scan abdomen and pelvis at 90 seconds
- Reconstructions:
 - All scans, all phases are to be reconstructed in three planes: axial, coronal, sagittal lined up with the patient (not the table) using a 3 mm slice width (or 3.75 mm if the scanner cannot create 3 mm) and 3 mm slice increment. If the patient is lying oblique (RPO or LPO) on the table, sagittal and coronal images must be aligned with the patient.

	Ax	Cor	Sag	Ax	Cor	Sag	Ax	Cor	Sag
Slice	3x3	3x3	3x3	3x3	3x3	3x3	3x3	3x3	3x3
Scan	W/O	W/O	W/O	35 sec	35 sec	35 sec	90 sec	90 sec	90 sec
Series Description	AX W/O	COR W/O	SAG W/O	AX EARLY ARTERIAL	COR EARLY ARTERIAL	SAG EARLY ARTERIAL	AX PORTAL VENOUS	COR PORTAL VENOUS	SAG PORTAL VENOUS

Cystogram

- 20 ml of Isovue 370 in 500 ml saline bag (do not remove any saline from bag)
- Scan Range: Top of bladder to below perineum
- Full bladder
- Reconstructions:
 - All scans, all phases are to be reconstructed in three planes: axial, coronal, sagittal lined up with the patient (not the table) using a 3 mm slice width (or 3.75 mm if the scanner cannot create 3 mm) and 3 mm slice increment. If the patient is lying oblique (RPO or LPO) on the table, sagittal and coronal images must be aligned with the patient.

	Ax	Cor	Sag
Slice	3x3	3x3	3x3
Series Description	AX +C	COR+C	SAG+C

- **Post void:**

	Ax	Cor	Sag
Slice	3x3	3x3	3x3
Series Description	AX DEL	COR DEL	SAG DEL

Enteroclysis:

- Procedure: Nasojejunal tube placed in fluoroscopy and small bowel infused with negative contrast
 - Some sites will infuse positive contrast.
- IV Contrast: optional
 - Rate: 3cc/sec
- Scan Range: Dome diaphragm to pubic symphysis
- Reconstructions:
 - All scans, all phases are to be reconstructed in three planes: axial, coronal, sagittal lined up with the patient (not the table) using a 3 mm slice width (or 3.75 mm if the scanner cannot create 3 mm) and 3 mm slice increment. If the patient is lying oblique (RPO or LPO) on the table, sagittal and coronal images must be aligned with the patient.

	Ax	Cor	Sag
Slice	3x3	3x3	3x3
Series Description	AX +C	COR +C	SAG +C

Enterography

- Patient Prep: Clear liquids after midnight.
- Oral Contrast: 450 ml volume (or local negative contrast agent) 60, 45 and 30 min prior to scan. 500 ml water 15 min prior to scan, if patient can tolerate.
- IV Contrast:
- Rate: 3mL/sec
- Timing: 70 sec
- Scan Range: Dome diaphragm to pubic symphysis
- Reconstructions:
 - All scans, all phases are to be reconstructed in three planes: axial, coronal, sagittal lined up with the patient (not the table) using a 3 mm slice width (or 3.75 mm if the scanner cannot create 3 mm) and 3 mm slice increment. If the patient is lying oblique (RPO or LPO) on the table, sagittal and coronal images must be aligned with the patient.

	Ax	Cor	Sag
Slice	3x3	3x3	3x3
Series Description	AX +C	COR +C	SAG +C

Liver (Multi-Phase)

- IV Contrast: .65 ml/pound with 135 ml max
 - ** Use arterial bolus tracking whenever possible
 - Rate 4 cc/sec
 - Saline flush: 50 ml at 4 cc/sec
 - IV access: 20 gauge or larger
- Scan Range: Above dome of liver to iliac crest
- Reconstructions:
 - All scans all phases are to be reconstructed in three planes: axial, coronal, sagittal lined up with the patient (not the table) using a 3mm slice width (or 3.75 mm if the scanner cannot create 3 mm) and 3 mm slice increment. If the patient is lying oblique (RPO or LPO) on the table, sagittal and coronal images must be aligned with the patient.
- Pelvis: If a pelvis is ordered, please go through the pelvis on the 75 second (Portal Venous phase) only.
- If order includes Chest (i.e. Chest/Abdomen/Pelvis) scan times can be 25 sec / 75 sec / and 5-minute delay, if scanner cannot accommodate 35 sec.
- If patient is status post Interventional Radiology ablation therapy, then also ADD CT WITHOUT through the same area.

		Ax			Cor	
Slice	3x3	3x3	3x3	3x3	3x3	3x3
Scan	35 sec or Bolus	75 sec or Bolus	5 min or Bolus	35 sec or Bolus	75 sec or Bolus	5 min or Bolus
Series Description	AX LATE ARTERIAL	AX PORTAL VENOUS	AX DEL	COR LATE ARTERIAL	COR PORTAL VENOUS	CORDEL

	Sag	
3x3	3x3	3x3
35 sec or Bolus	75 sec or Bolus	5 min or Bolus
SAG LATE ARTERIAL	SAG PORTAL VENOUS	SAG DEL

● **Without Bolus Tracker**

Scan abdomen at 35 seconds (arterial phase)
 Scan abdomen at 75 seconds (portal phase)
 Scan abdomen at 5 minutes (delayed phase)

** **(Preferred Method) is With Arterial Bolus Tracker**

Place Tracker at aorta at the diaphragms
 18 seconds after tracker reaches 120 HU, scan abdomen (arterial phase)
 48 seconds after tracker reaches 120 HU, scan abdomen (portal phase)
 5 minutes after tracker reaches 120 HU, scan abdomen (delayed phase)

Pancreas

- Oral Contrast: Water
- IV Contrast: .65 ml/pound with 135 ml max
- Rate: 4 - 5cc/sec.
- Scan at 40 and 80 sec.
- Scan Range: Above dome of liver to iliac crest
- Reconstructions:
 - All scans, all phases are to be reconstructed in three planes: axial, coronal, sagittal lined up with the patient (not the table) using a 3 mm slice width (or 3.75 mm if the scanner cannot create 3 mm) and 3 mm slice increment. If the patient is lying oblique (RPO or LPO) on the table, sagittal and coronal images must be aligned with the patient.

	Ax	Ax	Cor	Cor	Sag	Sag
Slice	3x3	3x3	3x3	3x3	3x3	3x3
Scan	40 sec	80 sec	40 sec	80 sec	40 sec	80 sec
Series Description	AX EARLY ARTERIAL	AX PORTAL VENOUS	COR EARLY ARTERIAL	COR PORTAL VENOUS	SAG EARLY ARTERIAL	SAG PORTAL VENOUS

Radiation Oncology Therapy Planning Protocol

- Reconstructions:
 - All scans, all phases are to be reconstructed in three planes: axial, coronal, sagittal lined up with the patient (not the table) using a 3 mm slice width (or 3.75 mm if the scanner cannot create 3 mm) and 3 mm slice increment. If the patient is lying oblique (RPO or LPO) on the table, sagittal and coronal images must be aligned with the patient.
 - Add AX MIP 7x3 mm to chest portion of the protocol.

	AX Chest	AX A/P	Ax Chest	AX Chest MIP	Cor Chest	Cor A/P	Sag Chest	Sag A/P
Slice	3x3	3x3	3x3	7x3mm	2x2	3x3	2x2	3x3
Series Description	AX CH	AX	AX LUNG	AX MIP	COR CH	COR	SAG CH	SAG
Filter/ Recon Algorithm	Body	Body	Lung	Body	Body	Body	Body	Body

Renal Mass

3-phase (split contrast bolus) protocol for patients under 35 years old

1. Scan #1: abdomen without. Use kVp 100 or less, if possible (to increase conspicuity of iodine).
2. Administer first half of IV contrast media at 3 ml/sec
3. Wait 7 minutes.
4. Administer second half of IV contrast media at 3 ml/sec
5. Scan #2: abdomen beginning 40 seconds after start of second injection. Use kVp 100 or less, if possible.
6. Scan #3: abdomen (and pelvis if ordered) beginning 90 seconds after start of second injection. Use kVp 100 or less, if possible.

4-phase (single contrast bolus) protocol for patients 35+ years old

1. Scan #1: abdomen without. Use kVp 100 or less, if possible (to improve conspicuity of iodine)
 2. Administer contrast media at 3 ml/sec
 3. Scan #2: abdomen beginning 40 seconds after start of injection. Use kVp 100 or less, if possible.
 4. Scan #3: abdomen beginning 90 seconds after the start of contrast media injection
 5. Wait 7 minutes.
 6. Scan #4: abdomen (and pelvis if ordered) beginning 9 minutes after the start of contrast media injection
- Reconstructions:
 - All scans, all phases are to be reconstructed in three planes: axial, coronal, sagittal lined up with the patient (not the table) using a 3 mm slice width (or 3.75 mm if the scanner cannot create 3 mm) and 3 mm slice increment. If the patient is lying oblique (RPO or LPO) on the table, sagittal and coronal images must be aligned with the patient.

	Ax	Ax	Cor	Cor	Sag	Sag
Slice	3x3	3x3	3x3	3x3	3x3	3x3
Scan	W/O	With	W/O	With	W/O	With
Series Description	AX	AX +C	COR	COR +C	SAG	SAG +C

Abdomen and Pelvis

- Routine Abd/Pelvis
- (Abdomen only & Pelvis Only)
- Oral Contrast only for following indications
 - Ovarian Cancer,
- IV Contrast:
 - Use P3t if available with max of 135 ml
 - Rate: 3cc/sec
 - Timing: 70 second
 - Scan Range: Dome diaphragm to pubic symphysis
 - Abdomen: Dome diaphragm through Iliac Crest
 - Pelvis only: Iliac Crest to below perineum
- Reconstructions:
 - All scans, all phases are to be reconstructed in three planes: axial, coronal, sagittal lined up with the patient (not the tables using a 3 mm slice width (or 3.75 mm if the scanner cannot create 3 mm) and 3 mm slice increment. If the patient is lying oblique (RPO or LPO) on the table, sagittal and coronal images must be aligned with the patient.
- Pregnant patient for appendicitis: Please change order to MRI Abdomen/Pelvis without contrast

	Ax	Cor	Sag
Slice	3x3	3x3	3x3
Series without or oral only	AX	COR	SAG
Series IV	AX +C	COR +C	SAG +C

CT Colonography

Anatomical Coverage:	Entire Colon
Contrast:	CO2 via insufflator, No PO or IV contrast.
Phase of Inspiration:	Inspiration
Slice Thickness:	3 mm / 1 mm for reformats
Slice Interval:	3 mm / 1 mm for reformats
Superior Aspect:	2 cm above colon on AP scout
Inferior Aspect:	2 cm below rectum
Scanning and Procedure:	Scan 1 = Prone & Scan 2 = Supine
Storage:	PACs, Scout, Axial, MPR, Colon fly through software if available
Prep:	Must perform CT colonography prep prior to study. ** Reference CT Colonography Prep Instructions NPO 6 – 8 hours prior to study except sips of water and meds. Do not scan if patient has eaten within 1.5 hours before study.
Comments:	Whether patient is post Colonoscopy or prepping for just a colonography they should follow the Radiologists protocol for CT Colonography if post colonoscopy and a biopsy was done, it must be scheduled 4 weeks post biopsy per Radiologists.
Indication:	Rectal bleeding, failed colonoscopy, sigmoid redundancy

	Ax
Slice	3 x 1
Scan	W/O
Series Description	AX

CT Venogram Abdomen/Pelvis

- INDICATION: May thurner, ilio caval thrombosis, IVC atresia, upper femoral, vein DVT
- REGION OF INTEREST: Abdomen, pelvis, upper thigh
- COVERAGE: 1cm above the diaphragm to mid-thigh
- INTRAVENOUS CONTRAST:
 - <200 lb 100 mL of isovue 370
 - 200+ lb 135 mL isovue 370
 - Rate: 2.5mL/sec
 - Scan delay: 100 second
- No oral contrast
- SLICE THICKNESS: 2 mm
- SLICE INTERVAL: 2 mm
- PITCH: 1.0
- Curved MPR only of the ilio caval system with the 100 second delay

	AX	COR MIP	SAG MIP	COR REFORMAT	SAG REFORMAT	Right ilio caval cMPR (curved MPR)	Left ilio caval cMPR (curved MPR)
SLICE	2x2	7X3	7X3	3X3	3X3	3d lab	3d lab
SCAN	WITH CONTRAST	WITH CONTRAST	WITH CONTRAST	WITH CONTRAST	WITH CONTRAST	WITH CONTRAST	WITH CONTRAST
SERIES DESCRIPTION	AX+C	COR MIP +C	SAG MIP +C	COR +C	SAG +C	Right +C cMPR	:EFT +C cMPR

CTA Abdomen & Pelvis with Runoff

REGION OF INTEREST: Abdominal Pelvic and Legs
COVERAGE: Dome of Liver through Feet
INTRAVENOUS CONTRAST: Non-Ionic 100 ml (135 ml maximum)
PHASE OF RESPIRATION: Inspiration
SLICE THICKNESS: 2 mm
SLICE INTERVAL: 2 mm
PITCH: No greater than 2
RECONSTRUCTION: Axial, Cor MPR, Sag MPR
Axial MIP, COR MIP and Sagittal MIPs 7 mm x 3 mm
Sagittal and Coronal Reformats

Scan 1: Topogram 1536 mm or 1970 mm

Scan 2: Without from dome of liver through feet

Scan 3: With IVC bolus tracker on Aorta near renal arteries; dome of liver through knees

Scan 4: With from knees to toes directly after scan 2

Comments

- Thin set of images (1 mm x 0.5 mm) on IV study sent to 3DR labs for 3D vascular reformats
- MIPs done on all IV Imaging
- MPR's done on all w/o and with imaging

INDICATION: Vascular Disease

	Ax	Ax	AX MIP	Cor MIP	Sag MIP	Cor Reformat	Sag Reformat
Slice	2 x 2	2 x 2	7 X 3	7 X 3	7 X 3	3 X 3	3 X 3
Scan	W/O	WITH	WITH	WITH	WITH	WITH	WITH
Series Description	AX	AX +C	AX MIP +C	COR MIP +C	SAG MIP +C		

Chest, Abdomen and Pelvis With (Routine)

- Oral Contrast: 1.5 – 2 hour prep.
- Give additional cup of contrast when patient arrives in department.
- IV Contrast:
 - Use P3t if available with max of 135 ml
 - Rate: 3mL/sec
 - Scan Range: Chest: Thoracic inlet through all the lung
 - Abdomen/Pelvis: Dome of diaphragm through pubic symphysis.
 - Timing:
 - Chest: 35 sec
 - Abdomen & Pelvis: 75 sec
- Reconstructions:
 - All scans, all phases are to be reconstructed in three planes: axial, coronal, sagittal lined up with the patient (not the table) using a 3 mm slice width (or 3.75 mm if the scanner cannot create 3 mm) and 3 mm slice increment. If the patient is lying oblique (RPO or LPO) on the table, sagittal and coronal images must be aligned with the patient.
 - Add AX MIP 7x3 mm to chest portion of the protocol.
- Note: Exam does not need scanned without, only with IV and Oral.

	Ax Chest	Ax A/P	Ax Chest	Ax Chest MIP	Cor Chest	Cor A/P	Sag Chest	Sag A/P
Slice	2x2	3x3	2x2	7x3mm	2x2	3x3	2x2	3x3
Scan	35 sec	75 sec	35 sec	35 sec	35 sec	75 sec	35 sec	75 sec
Series Description W/O IV	AX CH	AX	AX LUNG	AX MIP	COR CH	COR	SAG CH	SAG
Series Description IV	AX CH +C	AX +C	AX LUNG +C	AX MIP	COR CH +C	COR +C	SAG CH +C	SAG +C
Filter/Recon Algorithm	Body	Body	Lung	Body	Body	Body	Body	Body

Chest with or without contrast (Routine)

- Rate: 3mL/sec (if contrast ordered)
- Timing: 30 sec (if contrast ordered)
- Scan Range: Thoracic inlet through all the lung
- Scan at end of inspiration after hyperventilation
- **Lung Nodule**
 - If diagnosis for “lung nodule – initial or follow-up” do a routine Chest without.

	Ax	Ax	Ax	Cor	Sag
Size to PACS (mm)	2x2	2x2	7x3mm	2x2	2x2
Series Description without or oral only	AX	AX LUNG	AX MIP	COR	SAG
Series Description IV	AX +C	AX LUNG +C	AX MIP +C	COR +C	SAG +C
Filter/ Recon Algorithm	Body	Lung	Body	Body	Body

High Resolution Chest

- Prefer without contrast
- If exam is ordered with IV contrast, please confirm with ordering physician whether contrast is necessary, as contrast is not typically given for High Resolution Chest, except in certain circumstances.
- If ordered for an indication other than interstitial lung disease, please confirm the indication with the ordering provider and request modification of the order to routine chest CT, if high resolution is not indicated.
 - Rate: 3mL/sec: Scan Range: Chest: Thoracic inlet through all the lungs
 - Order of scan does not matter
 - In the event that a patient cannot lay prone, please obtain a decubitus with the affected side up view. Same reconstructions apply to this (these) views as the prone.

	Ax Prone Inspiration	Ax Supine Inspiration	Ax Supine Inspiration	Ax Supine Expiration	Ax MIP from Supine Insp	Cor MIP from Supine Insp	Cor from Sup Insp	Sag from Sup Insp
Size to PACS (mm)	2x2	2x2	2x2	2x2	7x3mm	7x3	2x2	2x2
Series Description without or oral only	AX PRONE	AX INSP LUNG	AX INSP	AX EXP	AX MIP	COR MIP	COR	SAG
Filter/Recon Algorithm	Lung	Lung	Body	Lung	Body	Body	Body	Body

Chest Angio Protocol PE

- Oral Contrast: None
- IV Contrast: Rate: 3.5 - 4 mL/sec
- Angiocath: 18 gauge or larger (smaller number) preferred.
- Timing: Typically, auto-timing ROI goes on RT Pulmonary Artery, but varies with scanner
- Scan Range: Chest: Thoracic inlet through all the lungs.
- Breathing instructions: Stop breathing - unless too SOB, and then quiet breathing.

	Ax	Cor	Sag	Ax Lung	Ax MIP	Sag MIP	Cor MIP	Left Oblique MIP	Right Oblique MIP
Size to PACS (mm)	2x2	2x2	2x2	2x2	7x3mm	5x3	5x3	5x3	5x3
Series Description without or oral only	AX +C	COR +C	SAG +C	AX LUNG +C	AX MIP +C	SAG MIP +C	COR MIP +C	OBL MIP L	OBL MIP R
Filter/Recon Algorithm	Body	Body	Body	Lung	Body	Body	Body	Body	Body

Calcium Score

- Scan Range (top to bottom) is through heart:
- Scan at end inspiration
- Include calcium score color images and score results document.
- Send to PACS: small field of view images (to heart) with and without color coronary calcium mapped.
- Send to PACS: Large field of view images (to entire body or largest possible based on scan) 2 mm thick / every 2 mm (AXIAL (lung reconstruction kernel), and SAGITTAL, and CORONAL) planes
- Send to PACS: Large field of view images (to the entire body or largest possible based on scan), MIPS 7 mm thick / every 3 mm.

Plane	Ax	Ax	Ax	Ax	Cor	Sag
Size to PACS (mm)	2x2	2x2	2x2	7x3mm	2x2	2x2
FOV Small = to heart or requested area Large = to entire body (or as large as possible)	Small Calcium color map	Small No color map	Large	Large	Large	Large
Series Description	AX	AX	AX Lung	AX MIP	COR	SAG
Series Description IV (blank if none)						
Filter/ Recon Algorithm	Body	Body	Lung	Body	Body	Body
Documents to be sent to PACs include:	Score table	Score graph				

Coronary Overread

- Scan Range (top to bottom) is through heart or as directed by Cardiology or Vascular Surgery protocol
- Scan at end inspiration (or if different according to protocol)
- Send to PACS: Small field of view images (to heart or protocol area of interest)
- Send to PACS: Large field of view images (to entire body or largest possible based on scan) 2 mm thick / every 2 mm (AXIAL (lung and body reconstruction kernels), and SAGITTAL, and CORONAL) planes
- Send to PACS: Large field of view images (to the entire body or largest possible based on scan), MIPS 7 mm thick / every 3 mm.

Plane	Ax	Ax	Ax	Cor	Sag	3Ds / and other images
Size to PACS (mm)	2x2	2x2	7x3mm	2x2	2x2	
FOV Small = to heart or requested area Large = to entire body (or as large as possible)	Large	Large	Large	Large	Large	Per service protocol
Series Description	AX	AX Lung	AX MIP	COR	SAG	
Series Description IV (blank if none)	Ax +C	Ax LUNG +C	AX MIP +C	COR +C	SAG +C	
Filter/ Recon Algorithm	Body	Lung	Body	Body	Body	

Aortic Dissection – CT Chest without and CTA Chest, Abdomen, & Pelvis with contrast

- IV Contrast:
 - Oral Contrast: None
 - IV: 18 gauge
 - Use P3t if available with max of 135 ml
 - Rate: 3.5 - 4mL/sec
 - Timing: Typically, auto-timing ROI goes in descending aorta at the level of pulmonary artery and may depend on the speed of scanner.
 - Use gating on patient
- Scan Range:
 - Chest without portion: Thoracic inlet through all the lung.
 - CTA portion: Thoracic inlet through proximal superficial femoral artery (proximal 1/3 of thigh)
- Reconstructions:
 - AX MIP 7 x 3 mm to chest portion of the protocol.
 - SAG MIP 5 x 5 for post contrasted chest, abdomen, and pelvis

	Ax Chest	Ax Chest	Ax Chest MIP	Ax C/A	Cor C/A	Sag C/A	Sag C/A MIP
Slice	2 x 2	2 x 2	7 x 3mm	2 x 2	2 x 2	2 x 2	5 x 5
Scan	without	without	without	timed	timed	timed	timed
Series Description W/O IV	AX CH	AX LUNG	AX MIP				
Series Description IV				AX CH ABD +C	COR CH ABD +C	SAG CH ABD +C	SAG CH ABD + C MIP
Filter/Recon Algorithm	Body	Lung	Body	Body	Body	Body	Body

Esophogram

- Order as a CT chest with & without PO contrast media (No IV contrast)
- This replaces the fluoroscopic esophogram for esophageal rupture/leak.

- Mix 20 ml Isovue 370 in 12 ounces (350 ml) water. Divide the contrast media into two cups, each containing 6 ounces.

- SCAN 1 (NO CONTRAST - SUPINE):
 - Place patient supine on CT scanner. Obtain scout views from the skull base to the iliac crests.
 - Perform very low dose CT scan from bottom of mandible to bottom of stomach without any contrast at all (no IV or oral).

- SCAN 2 (POST-CONTRAST - SUPINE):
 - With patient supine, turn the head to one side and ask the patient to drink 6 ounces of dilute Isovue using a straw, and immediately repeat the scan from bottom of mandible to bottom of stomach.

- SCAN 3 (POST-CONTRAST - PRONE):
 - If the patient is able, turn the patient prone, and obtain scout views from the skull base to iliac crest. Plan the 3rd scan from bottom of mandible to bottom of stomach. Then ask the patient to turn the head to the side and drink 6 ounces of dilute Isovue using a straw. Immediately scan from bottom of mandible to bottom of stomach.

- IF THE PATIENT CANNOT SWALLOW
 - Ask the referring physician to place a nasoesophageal tube with the tip of the tube just BELOW the carina. The position of the tube must be evaluated on the scout views to make sure that it is NOT in the trachea. Ask the referring physician or nurse to adjust the tube position, if necessary. Perform the NO CONTRAST - SUPINE scan as outlined above. Then do the POST-CONTRAST scans as outlined above, with one exception: Inject only 50 ml dilute contrast media through the tube before each scan.

CT Low Dose Lung Screening

- No oral or IV contrast
- Positioning: Center the patient supine within the gantry with arms above head.
- Scan Range: Top of lungs through the bottom of lungs
- Respiration: Patient should be instructed to hold his/her breath at end of inspiration during entire scan.
- Radiation Dose Management: CTDI_{vol} must be ≤ 3.0 mGy for a standard sized patient as measured using a 32-cm diameter CTDI phantom.
 - By definition, a standard sized patient is approximately 5'7" and 155 pounds or 170 cm and 70 kg, with BMI = 24.

Lung Screening Follow-up

- This exam should be used for 3 and 6-month short-term follow-up lung cancer screening exams.
 - If this is an annual lung cancer screening follow-up exam, perform using the CT Low Dose Lung Screening protocol.
- No oral or IV contrast
- Positioning: Center the patient supine within the gantry with arms above head.
- Scan Range: Top of lungs through the bottom of lungs
- Respiration: Patient should be instructed to hold his/her breath at end of inspiration during entire scan.
- Image quality/radiation dose must be higher than a low dose lung screening exam for diagnostic purposes, but should be lower than the image quality/radiation dose of a standard CT chest without.

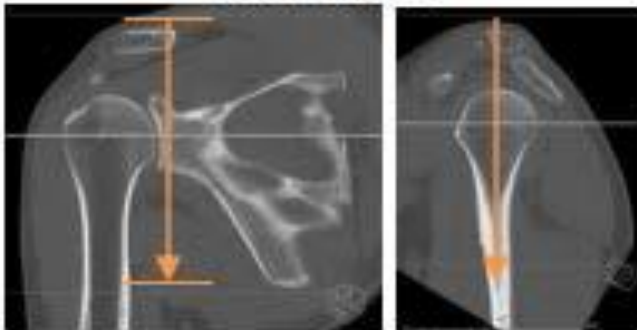
	Ax	Ax Lung	Cor	Sag	Ax MIP	Cor MIP
Size to PACS (mm)	2x2	2x2	2x2	2x2	7x3	7X3
Series Description	AX	Ax LUNG	COR	SAG	AX MIP	COR MIP
Filter/Recon Algorithm	Soft Tissue	Lung	Soft Tissue	Soft Tissue	Soft Tissue	Soft Tissue

Shoulder

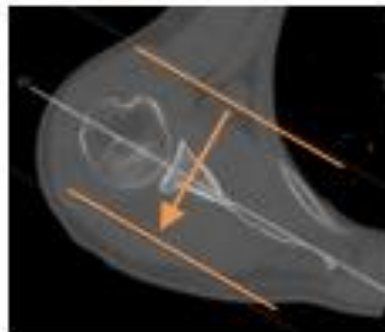
- REGION OF INTEREST: Shoulder
- FOV: Smallest possible to include lateral skin surface and scapula
- START: 1 cm superior to AC joint
- END: 1 cm inferior to scapula
- RECONSTRUCTION: Oriented with respect to glenoid at mid-level
- INDICATION: Pain, swelling, limited range of motion, trauma, mass, infection, preoperative planning
- PATIENT POSITION: Supine with affected arm down by side with palm up (externally rotated); Contralateral arm above head

	Ax (Bone)	Sag (Bone)	Cor (Bone)	Ax (Soft)	Sag (Soft)	Cor (Soft)
Slice	2 x 2	2 x 2	2 x 2	2 x 2	2 x 2	2 x 2
Scan	W/O	W/O	W/O	W/O	W/O	W/O
Series Description	AX BONE	SAG BONE	COR BONE	AX SOFT	SAG SOFT	COR SOFT

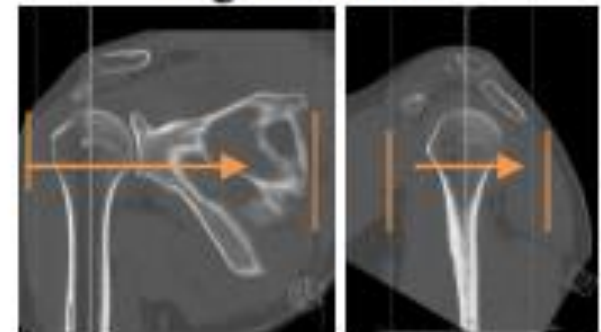
Axial MPR



Coronal MPR



Sagittal MPR



Long bone (Humerus, Radius/Ulna, Femur, Tibia/Fibula)

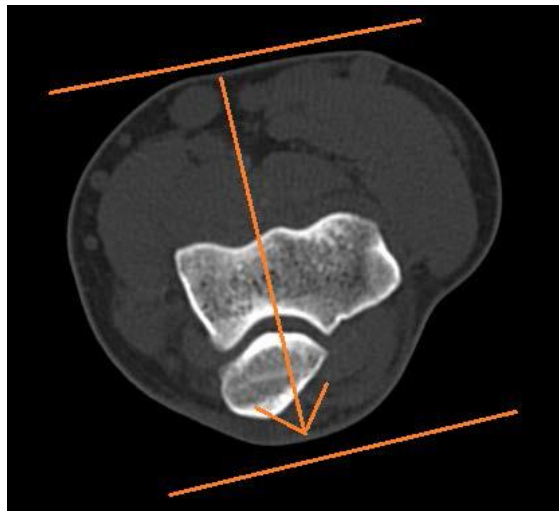
- REGION OF INTEREST: Humerus OR Radius/Ulna OR Femur OR Tibia/Fibula
- SCAN RANGE: Cover entire long bone in the field of view to include surrounding soft tissues to skin surface
- FOV: Smallest possible to include skin surface
- RECONSTRUCTION: Axial reformats perpendicular to long bone diaphysis
Sagittal and coronal reformats parallel to the long bone diaphysis
- INDICATION: Pain, swelling, trauma, mass, infection, preoperative planning
- PATIENT POSITION: Most comfortable

	Ax (Bone)	Sag (Bone)	Cor (Bone)	Ax (Soft)	Sag (Soft)	Cor (Soft)
Slice	2 x 2	2 x 2	2 x 2	2 x 2	2 x 2	2 x 2
Scan	W/O	W/O	W/O	W/O	W/O	W/O
Series Description	AX BONE	SAG BONE	COR BONE	AX SOFT	SAG SOFT	COR SOFT

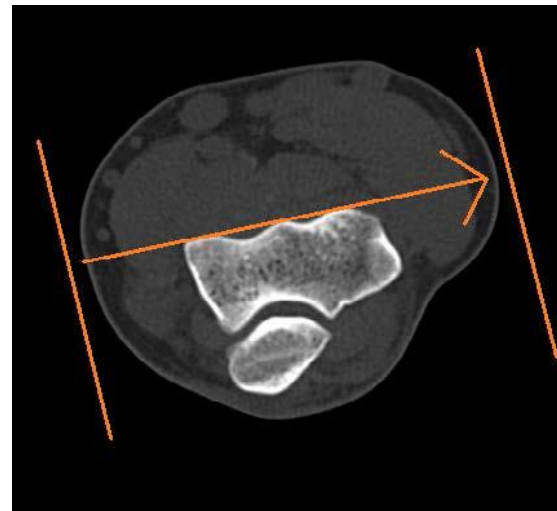
Elbow

- REGION OF INTEREST: Elbow
- FOV: Smallest possible to include skin surface
- START: 1 cm superior to distal humeral metadiaphysis
- END: 1 cm inferior to radial tuberosity
- RECONSTRUCTION: Axials oriented perpendicular to the humeral diaphysis and thru the inter-epicondylar line
Sagittal and coronal reformats parallel to the humeral diaphysis and perpendicular to the inter-epicondylar line
- INDICATION: Pain, swelling, limited range of motion, trauma, mass, infection, preoperative planning
- PATIENT POSITION: Supine or lateral decubitus with affected arm raised above patient's head; Elbow joint as straight as possible with palm up

	Ax (Bone)	Sag (Bone)	Cor (Bone)	Ax (Soft)	Sag (Soft)	Cor (Soft)
Slice	2 x 2	2 x 2	2 x 2	2 x 2	2 x 2	2 x 2
Scan	W/O	W/O	W/O	W/O	W/O	W/O
Series Description	AX BONE	SAG BONE	COR BONE	AX SOFT	SAG SOFT	COR SOFT



Coronal

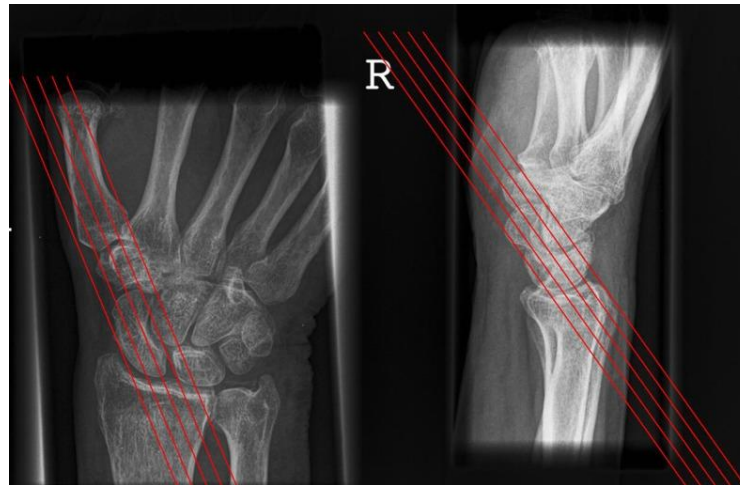


Sagittal

Wrist

- REGION OF INTEREST: Wrist
- FOV: Smallest possible to include skin surface
- START: 1 cm proximal to distal radial diaphysis
- END: 1 cm distal to the third metacarpal base
- RECONSTRUCTION: Axial is perpendicular to the wrist
Coronal and Sagittal along the long axis of the wrist
*Scaphoid view: Oblique reformat along the long axis of the scaphoid WHEN suspected scaphoid fracture
- INDICATION: Pain, swelling, limited range of motion, trauma, mass, infection, preoperative planning
- PATIENT POSITION: Prone with arm extended above patient's head; Affected wrist in isocenter of table with elbow extended and palm down

	Ax (Bone)	Sag (Bone)	Cor (Bone)	Ax (Soft)	Sag (Soft)	Cor (Soft)	*Scaphoid View (Bone)
Slice	1.5 x 1.5	2 x 2	2 x 2	1.5 x 1.5	2 x 2	2 x 2	1 x 1
Scan	W/O	W/O	W/O	W/O	W/O	W/O	W/O
Series Description	AX BONE	SAG BONE	COR BONE	AX SOFT	SAG SOFT	COR SOFT	SCAPHOID BONE



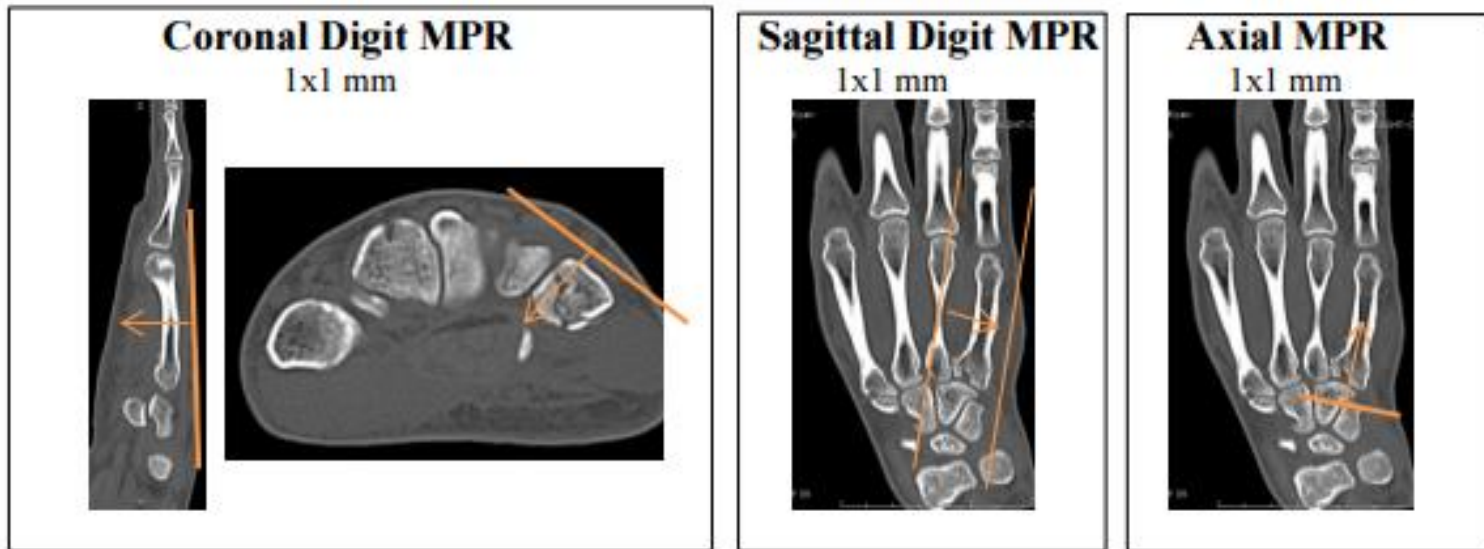
*Scaphoid View (for suspected scaphoid fracture)

Hand/Fingers:

- REGION OF INTEREST: Hand/Fingers
- FOV: Smallest possible to include skin surface
- START: 1 cm proximal to DRUJ
- END: 1 cm distal to the third digit fingertip
- RECONSTRUCTION: Hand axial is perpendicular to the hand with coronal and sagittal perpendicular
Finger axial is perpendicular to the affected digit with coronal and sagittal perpendicular
- INDICATION: Pain, swelling, limited range of motion, trauma, mass, infection, preoperative planning
- PATIENT POSITION: Prone with arm extended above patient's head; Affected hand in isocenter of table with elbow extended and palm down

	Ax (Bone)	Sag (Bone)	Cor (Bone)	Ax (Soft)	Sag (Soft)	Cor (Soft)
Slice (Hand)	1.5 x 1.5	2 x 2	2 x 2	1.5 x 1.5	2 x 2	2 x 2
Slice (Finger)	1 x 1	1 x 1	1 x 1	1 x 1	1 x 1	1 x 1
Scan	W/O	W/O	W/O	W/O	W/O	W/O
Series Description	AX BONE	SAG BONE	COR BONE	AX SOFT	SAG SOFT	COR SOFT

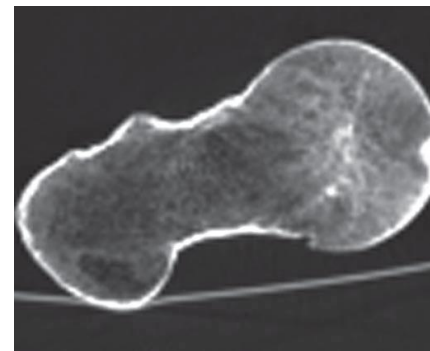
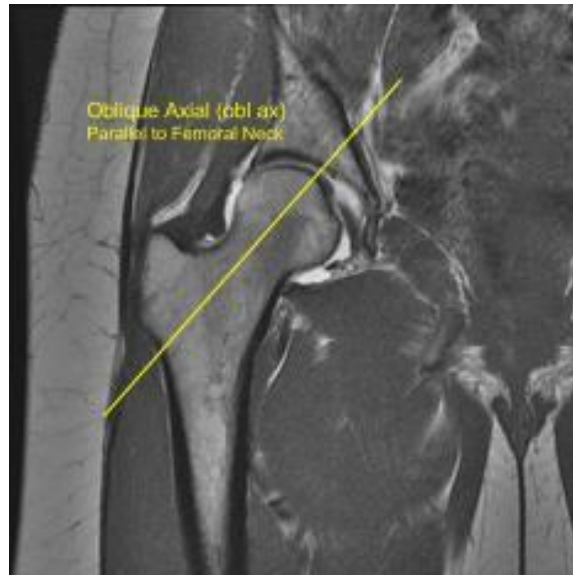
Specific Finger



Pelvis/Hip

- REGION OF INTEREST: Pelvis/Hip
- FOV: Smallest possible to include lateral skin surface; Hip images to include symphysis pubis
- START: 1 cm superior to the iliac crests
- END: 3 cm distal to the lesser trochanters
- RECONSTRUCTION: Axials oriented transverse thru the femoral heads; Coronal and sagittal are perpendicular
*Cam view: Oblique reformat parallel to the long axis of the femoral neck WHEN hip ordered
- INDICATION: Pain, swelling, limited range of motion, trauma, mass, infection, preoperative planning
- PATIENT POSITION: Patient supine, feet first; Legs flat on the table

	Ax (Bone)	Sag (Bone)	Cor (Bone)	Ax (Soft)	Sag (Soft)	Cor (Soft)	*Cam View (Bone)
Slice	2 x 2	2 x 2	2 x 2	2 x 2	2 x 2	2 x 2	2 x 2
Scan	W/O	W/O	W/O	W/O	W/O	W/O	W/O
Series Description	AX BONE	SAG BONE	COR BONE	AX SOFT	SAG SOFT	COR SOFT	CAM BONE

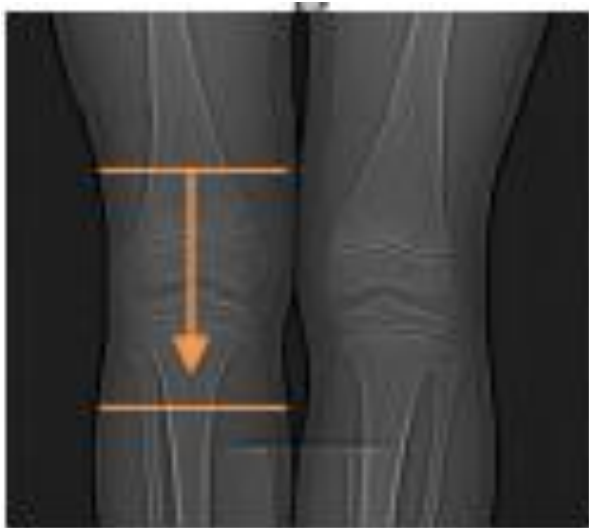

*Cam View (oblique axial) for hip CTs only

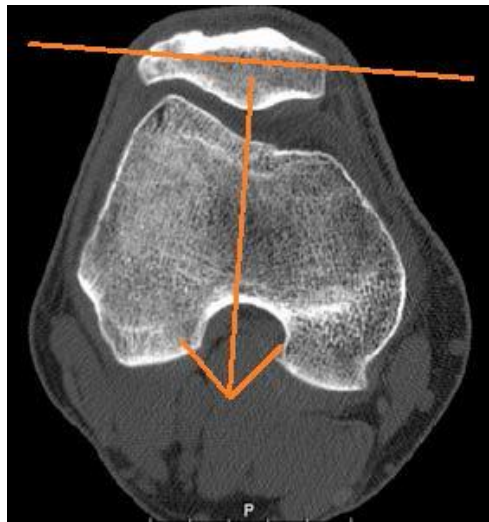Knee

- REGION OF INTEREST: Knee
- FOV: Smallest possible to include skin surface
- START: 3 cm proximal to patella
- END: 1 cm distal to the tibial tubercle and fibular head
- RECONSTRUCTION: Axial is perpendicular to the distal femur, tangential to the femoral condyles at the femorotibial joints
Coronal and sagittal are perpendicular to the femoral condyles
- INDICATION: Pain, swelling, limited range of motion, trauma, mass, infection, preoperative planning
- PATIENT POSITION: Patient supine, feet first; Legs flat on the table

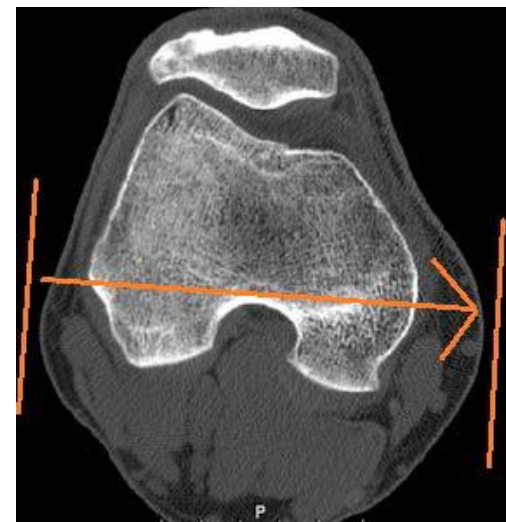	Ax (Bone)	Sag (Bone)	Cor (Bone)	Ax (Soft)	Sag (Soft)	Cor (Soft)
Slice	2 x 2	2 x 2	2 x 2	2 x 2	2 x 2	2 x 2
Scan	W/O	W/O	W/O	W/O	W/O	W/O
Series Description	AX BONE	SAG BONE	COR BONE	AX SOFT	SAG SOFT	COR SOFT



Axial



Coronal

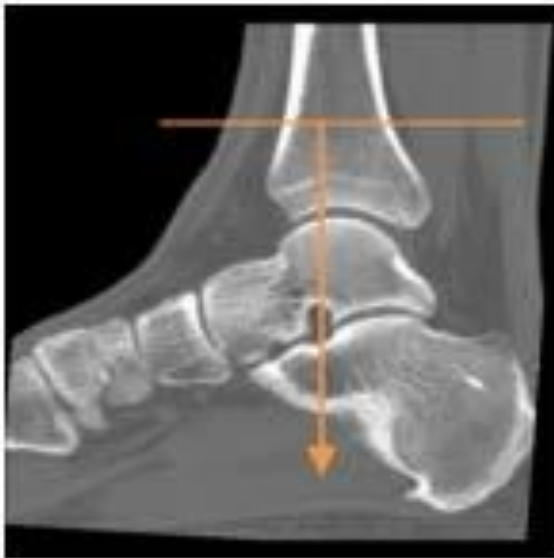

Sagittal

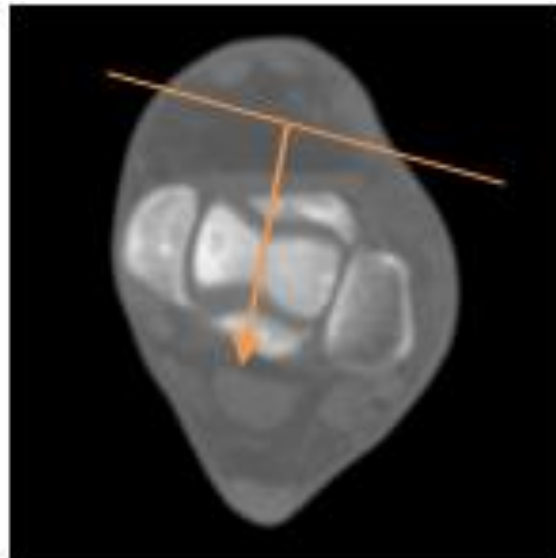
Ankle

- REGION OF INTEREST: Ankle
- FOV: Smallest possible to include skin surface and the metatarsal bases
- START: Distal tibia metadiaphysis
- END: Skin surface plantar to the calcaneus
- RECONSTRUCTION: Axial is perpendicular to the distal tibia
Coronal and sagittal perpendicular to the distal tib/fib joint (see images)
- INDICATION: Pain, swelling, limited range of motion, trauma, mass, infection, preoperative planning
- PATIENT POSITION: Patient supine, feet first; Toes pointing straight up with opposite leg bent at knee and out of scan

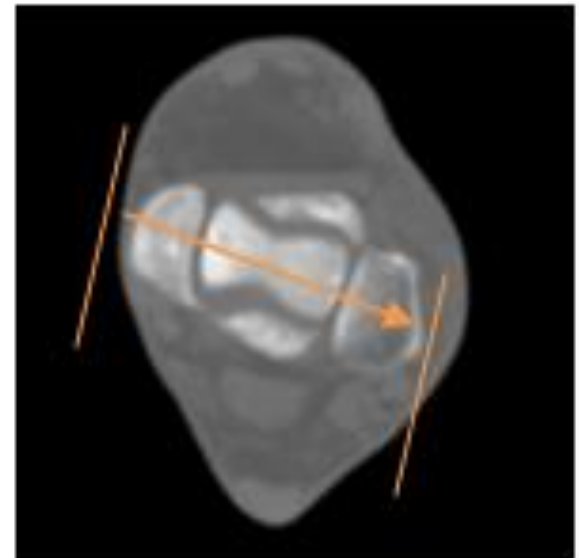
	Ax (Bone)	Sag (Bone)	Cor (Bone)	Ax (Soft)	Sag (Soft)	Cor (Soft)
Slice	2 x 2	2 x 2	2 x 2	2 x 2	2 x 2	2 x 2
Scan	W/O	W/O	W/O	W/O	W/O	W/O
Series Description	AX BONE	SAG BONE	COR BONE	AX SOFT	SAG SOFT	COR SOFT



Axial (source)



Coronal

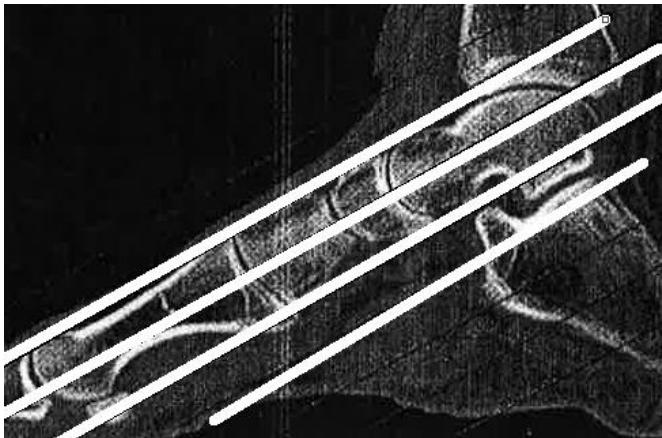


Sagittal

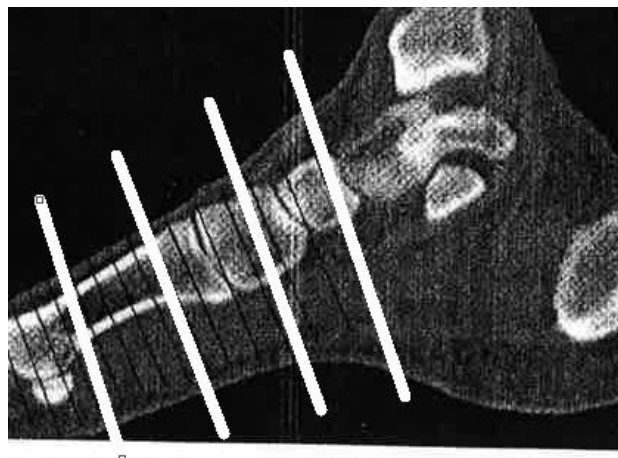
Foot/Toes

- REGION OF INTEREST: Foot/toes
- FOV: Smallest possible to include skin surface
- START/END: Oblique coronal source images from subtalar joint thru the toes
- RECONSTRUCTION: Optimal FOOT alignment oriented to the SECOND metatarsal; Optimal TOE alignment oriented to affected toe
- INDICATION: Pain, swelling, limited range of motion, trauma, mass, infection, preoperative planning
- PATIENT POSITION (IF NOT ANKLE):
 - Patient supine with knees bent and affected foot flat on the table; gantry angled perpendicular to the subtalar joint

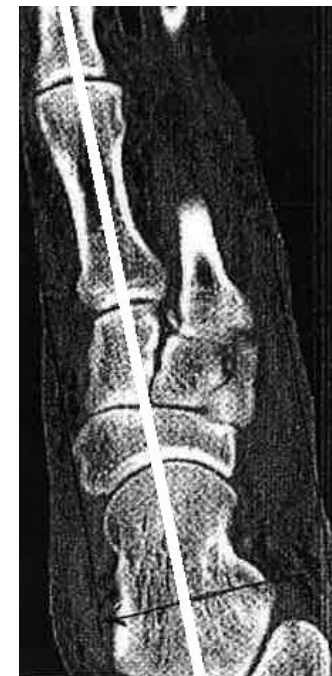	Ax (Bone)	Sag (Bone)	Cor (Bone)	Ax (Soft)	Sag (Soft)	Cor (Soft)
Slice	2 x 2	2 x 2	2 x 2	2 x 2	2 x 2	2 x 2
Scan	W/O	W/O	W/O	W/O	W/O	W/O
Series Description	AX BONE	SAG BONE	COR BONE	AX SOFT	SAG SOFT	COR SOFT



Axial



Coronal



Sagittal (prefer foot CT oriented to 2nd MT)

SPECIFIC TOE: Orient to the affected toe as shown on specific finger images (hand/finger section)