

THYROIDECTOMY / NECK ULTRASOUND

Date: _____ Tech: _____

Patient Name _____

DOB _____

MRN _____

History: ☐ Neck Mass ☐ R ☐ L ☐ Thyroid Cancer ☐ Neck Pain
☐ Thyroidectomy ☐ R ☐ L Date: _____
☐ Radioiodine ablation: ☐ R ☐ L Date: _____
☐ Enlarged Lymph Nodes ☐ R ☐ L ☐ Other: _____

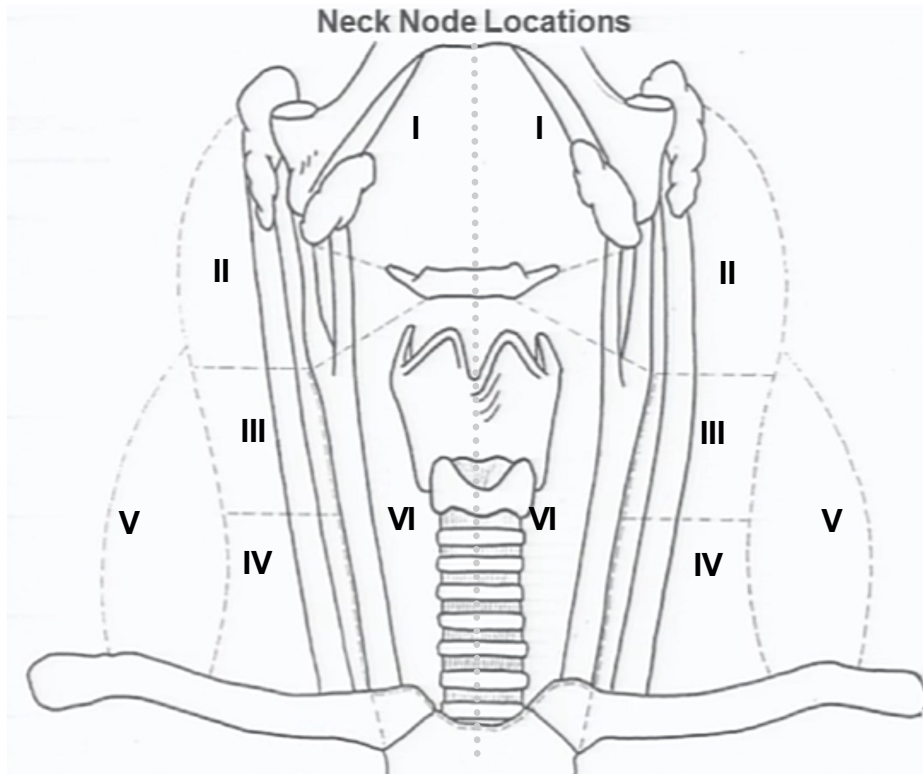
Abnormal features: Calcifications, Cystic areas, Absence of fatty hilum, Round shape (>0.5 short/long axis ratio). Abnormal blood flow

- Document size and location with # of each **Abnormal** lymph node on sketch
- # and Image each **Abnormal** lymph node in gray scale and color power
- Image normal nodes with measurement –document # seen in chart below

Suspicious

Right

Left



Right Neck:

of Normal Lymph nodes:

Level 1: # _____
 Level 2: # _____
 Level 3: # _____
 Level 4: # _____
 Level 5: # _____
 Level 6: # _____

Residual thyroid tissue? ☐ Yes ☐ No

RT: _____ x _____ x _____ cm

LT: _____ x _____ x _____ cm

Left Neck:

of Normal Lymph nodes:

Level 1: # _____
 Level 2: # _____
 Level 3: # _____
 Level 4: # _____
 Level 5: # _____
 Level 6: # _____